

medartis®

PRECISION IN FIXATION

SURGICAL TECHNIQUE

Orbital Plating System OPS 1.5

MODUS®
Midface



LITERATURE

1. Baumann, A., Ewers, R.
Use of the preseptal transconjunctival approach in orbit reconstruction surgery
J Oral Maxillofac Surg. 2001 Mar; 59(3): 287-91.
2. Ellis, E. 3rd, Tan, Y.
Assessment of internal orbital reconstructions for pure blowout fractures:
cranial bone grafts versus titanium mesh
J Oral Maxillofac Surg. 2003 Apr; 61(4): 442-53.
3. Hardt, N., Kuttenger, J.
Craniofacial Trauma
Springer-Verlag, Berlin Heidelberg, 2010: 97.
4. Hartstein, M.E., Roper-Hall, G.
Update on orbital floor fractures: indications and timing for repair
Facial Plast Surg. 2000; 16(2): 95-106.
5. Jaquiéry, C., Aeppli, C., Cornelius, P., Palmowsky, A., Kunz, C., Hammer, B.
Reconstruction of orbital wall defects: critical review of 72 patients
Int J Oral Maxillofac Surg. 2007 Mar; 36(3): 193-9.



Orbital Plating System OPS 1.5

CONTENTS

2	Literature
4	Introduction
4	Principle and Goal of Surgery
4	Advantages
4–5	Indications
5	Contraindications
5	Patient Information
5	Surgery Preparation
5	Instruments
5	Anaesthesia and Bedding
5	Post-Operative Treatment
5	Complications
6	Correlation between Orbital Floor Plate and Category
7–9	Surgical Technique
10	Information on Orbital Floor Plate Cutting

At a glance

Orbital Plating System OPS 1.5

INTRODUCTION

Orbital fractures appear in around half ^[3] of all cases involving a trauma of the skull, making them some of the most common fractures of the midface. Depending on the severity of the sequelae after orbital floor and wall fractures (such as globe motility constraints, enophthalmos, structural disorders or accompanying fractures) they should be treated surgically at the earliest stage after the trauma.

The aim of the surgical intervention is to reduce the orbit according to its former volume and the correct internal shape. At the same time trapped soft tissue must be lifted from the fracture line. Incorrect reduction of the orbit often leads to severe post-operative complications such as enophthalmos, hypoglobus or persistent diplopia.

The reduction of the orbit can be accomplished through various methods. The reconstruction with the 3D mesh orbital floor plate presented below is particularly apt for defects bigger than 1.5 cm². It also allows smaller approaches such as the transconjunctival approach. The OPS 1.5 orbital floor plates are easily malleable and can be cut without sharp burrs/edges according to the indication met.

PRINCIPLE AND GOAL OF SURGERY

Reduction of the orbital floor and wall (preferred fracture size ≥ 1.5 cm²). Reconstruction of the original form and volume.

ADVANTAGES

- Orbital floor plate as easily adaptable 3D titanium mesh ^[6] which allows for perfect reconstruction of the orbital structures
- Soft tissue protection: no sharp burrs/edges after cutting of the plate
- One implant design covers several indications
- Easy, fast and precise shaping of the plate thanks to the midface model and forming instrument

INDICATIONS

Reduction and fixation of the orbital floor and orbital wall (preferred fracture size ≥ 1.5 cm²) ^[5]:

Implant plates M-4440 and M-4442:

- **Category I**
Isolated defects of the orbital floor or medial wall, 1–2 cm², which do not exceed the anterior two thirds in the anterior-posterior projection.
- **Category II**
Defects of the orbital floor and/or medial wall > 2 cm², which do not exceed the anterior two thirds in the anterior-posterior projection. A bony structure at the medial ledge of the infra-orbital fissure is preserved.

Implant plates M-4444 and M-4446:

- **Category III**
Defects of the orbital floor and/or medial wall > 2 cm² which do not exceed the anterior two thirds in the anterior-posterior projection. Absence of a bony ledge at the medial aspect of the infra-orbital fissure.
- **Category IV**
Defects of the whole orbital floor and medial wall extended on the posterior thirds and without bony ledge at the medial aspect of the infra-orbital fissure.

CONTRAINDICATIONS

- Existing or suspected infections at or near the site of implantation
- Known allergies and/or hypersensitivity to foreign bodies
- Inferior or insufficient bone substance to securely fix the implant
- The treatment of at-risk groups is inadvisable

PATIENT INFORMATION *

Patients are extensively informed about the surgery and its risks. Nose blowing prohibition for approx. 2 weeks. Possible complications include wound healing disorder, lack of sensitivity in the cheek region, infection and malpositioning of the plate.

SURGERY PREPARATION *

- Perioperative administration of Penicillin (Amoxicillin/Clavulanacid) or Cephalosporin intravenously (up to 24h after operation), then orally 5 days in total
- Computer tomography of the orbit
- Orthoptic and ophthalmological assessment

INSTRUMENTS

In addition to general surgical instruments, MODUS OPS 1.5 instruments are used for precise shaping of the orbital floor plates.

ANAESTHESIA AND BEDDING *

The patient is intubated orally. Draping is done as usual after disinfection of the face.

POST-OPERATIVE TREATMENT *














- Administration of Penicillin (Amoxicillin/Clavulanacid) or Cephalosporin intravenously for the first 24h post-operatively, then orally for 5 days
- Hourly control of the pupils during the first 24h post-operatively
- Post-operative CT-scan control of the orbit
- No nose blowing for 2 weeks
- Sports prohibition for 4–6 weeks
- Re-checks after 1 week, 4 weeks, 6 months and 1 year post-operatively

COMPLICATIONS

- Screw loosening through insufficient fixation
- Hypersensitivity to metal or allergic reactions
- Bone necrosis, osteoporosis, insufficient revascularisation, bone resorption and bad bone building which might lead to early loss of fixation
- Soft tissue irritation and/or nerve damage through surgical trauma
- Early or late superficial as well as deep infections
- Heightened fibrous tissue reaction around the surgical field
- Malpositioning of the plate leading to post-operative enophthalmos, hypoglobus, or diplopia
- Entrapment of tissue with limited globe motility
- Secondary bleeding with retro-bulbar haematoma and optic nerve compression

* Treatment and recommendation according to University clinic for craniomaxillofacial surgery, Berne (Switzerland)

Correlation between Orbital Floor Plate and Category ^[5]

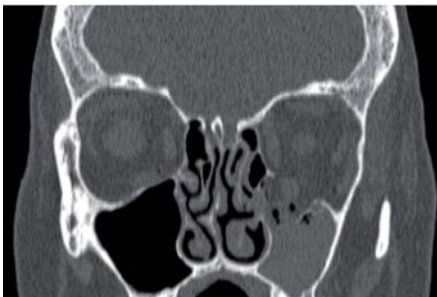
 <p>M-4440</p>	 <p>M-4442</p>				<p>Category I</p> <p>Isolated defects of the orbital floor or medial wall, 1–2 cm², which do not exceed the anterior two thirds in the anterior-posterior projection.</p>
 <p>M-4440</p>	 <p>M-4442</p>	 <p>M-4444</p>	 <p>M-4446</p>		<p>Category II</p> <p>Defects of the orbital floor and/or medial wall > 2 cm², which do not exceed the anterior two thirds in the anterior-posterior projection. Bony structure at the medial ledge of the infra-orbital fissure is preserved.</p>
		 <p>M-4444</p>	 <p>M-4446</p>		<p>Category III</p> <p>Defects of the orbital floor and/or medial wall > 2 cm² which do not exceed the anterior two thirds in the anterior-posterior projection. Bony structure at the medial ledge of the infra-orbital fissure is missing.</p>
		 <p>M-4444</p>	 <p>M-4446</p>		<p>Category IV</p> <p>Defects of the whole orbital floor and medial wall extended on the posterior thirds and without bony structure at the medial ledge of the infra-orbital fissure.</p>

Surgical Technique

Reduction of the orbital volume and form with the anatomically malleable 3D mesh orbital floor plate MODUS OPS 1.5

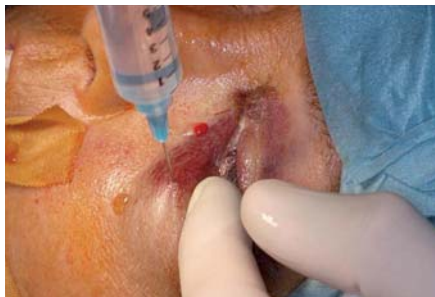Example and method according to Prof. Dr. Dr. T. Iizuka, Dr. Dr. M. Büttner and Dr. Dr. B. Schaller, University clinic for craniomaxillofacial surgery, Inselspital Berne (Switzerland)

Clinical Case



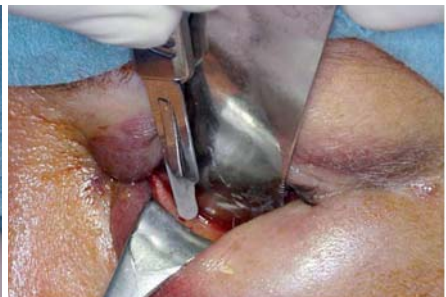STEP 1

Fracture of the left orbital floor according to category II ^[5] with a medial ledge preserved near the fissure orbitalis inferior. The M. rectus inferior lies in the fractured gap.



STEP 2

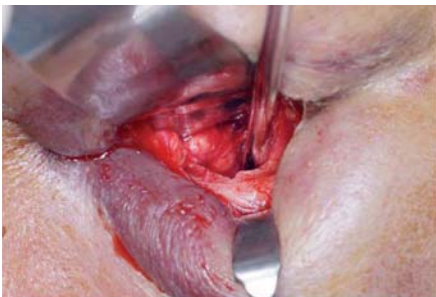
Small amounts of a vasoconstrictor are injected before the first cut underneath the tarsus and under protection of the lacrimal apparatus.



STEP 3

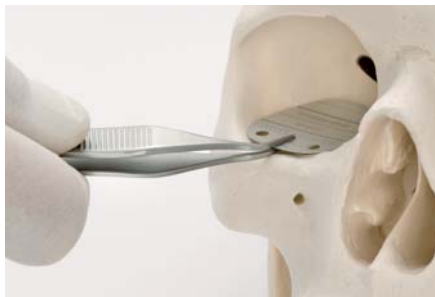Transconjunctival approach: It is either possible to dissect preseptally or retro-septally. The approach can be combined with a transcaruncular incision or a lateral canthotomy.

[5] See "Literature" (page 2)



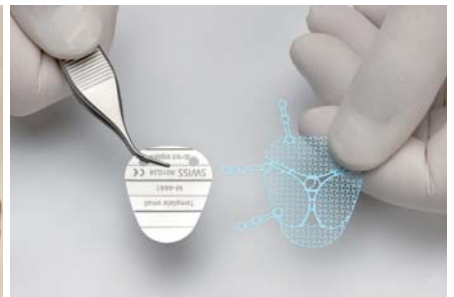STEP 4

Exposure of the site and removal of dislocated fragments from the maxillary sinus. After incision of the periorbita, exposure of the orbital floor underneath it. All the soft tissue must be held back with a retractor from the fracture gap.



STEP 5

Measure fracture size with bending template (M-4441/M-4443).




STEP 6

Choose suitable orbital floor plate according to the bending template.




STEP 7

If necessary cut the orbital floor plate with the mesh cutting pliers (M-2870) to a suitable shape. (Tips for cutting on page 10)



STEP 8

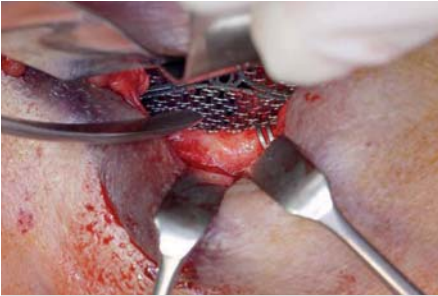Preform the orbital floor plate roughly in the midface model (M-2874) before insertion.



STEP 9

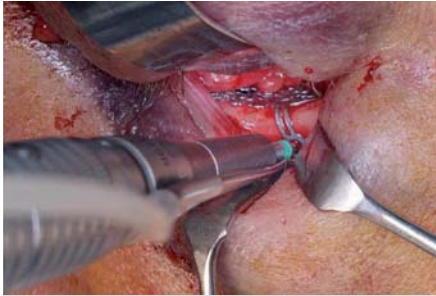
If necessary use bending template as insertion aid!

Note: Since the orbital floor plate is very flexible, it is necessary to handle it carefully when introducing it. In order to avoid undesired shaping of the plate, it is recommended to use the bending template as an insertion aid. The template is put underneath the plate, fixed with pliers and then introduced together into site. After placing the plate correctly the template has to be removed.



STEP 10

Place the orbital floor plate in site and shape with the aid of the forming instrument (M-2872).



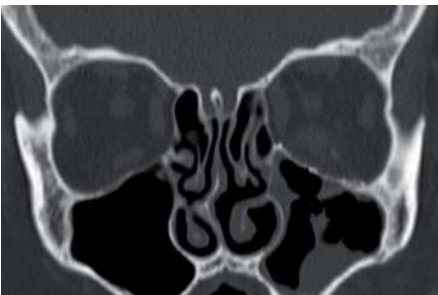
STEP 11

Pre-drill the necessary holes (twist drill with green colored ring).



STEP 12

Insert screws and close the wound.



STEP 13

Post-operative X-ray check-up.

Information on Orbital Floor Plate Cutting

According to the fracture type, the orbital floor plates can be cut in different ways along the bars. Possible cutting patterns are illustrated below:

A: Depending on the specific approach, fixation bars can be removed (cut either one hole off or the complete bar).

B: For a small anterior orbital floor fracture, in many cases the first mesh segment is sufficient (cutting lines from B to B).

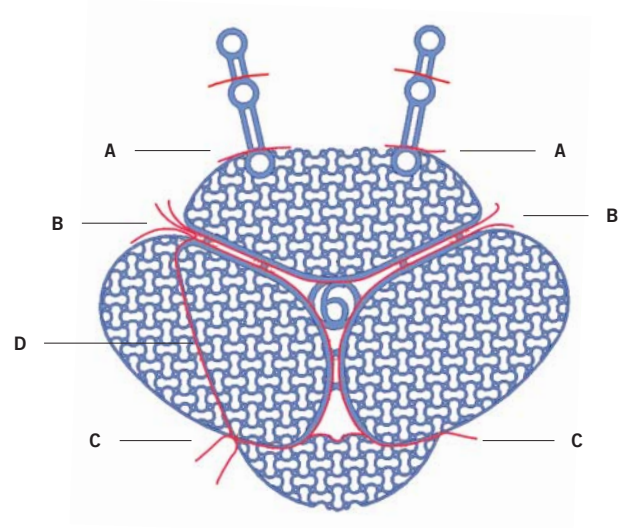
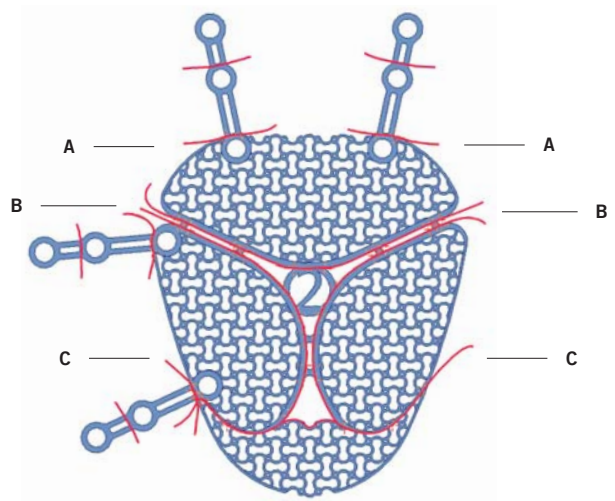
C: To reduce the risk of the infraorbital nerve being damaged, the front part of the orbital plate can be cut (cutting lines from C to C).

D: If only one orbital wall is fractured, one wing of the mesh can be cut off along the bar.

Combination of B and C:

For smaller defects, the anterior mesh segment and a lateral segment can be used (cutting lines from the starting point B diagonally to the end point C).

Depending on the approach, fixation bars of the plate can be trimmed. For transconjunctival approach, it is recommended to cut off the first holes of fixation bars.



MIDFACE-01010001_v1 / © 04.2011, Medartis AG, Switzerland. All technical data subject to alteration.

HEADQUARTERS

Medartis AG | Hochbergerstrasse 60E | 4057 Basel/Switzerland
P +41 61 633 34 34 | F +41 61 633 34 00 | www.medartis.com

SUBSIDIARIES

Australia | Austria | France | Germany | Mexico | New Zealand | Poland | UK | USA

For detailed information regarding our subsidiaries and distributors, please visit www.medartis.com

