


CASE REPORT



Fixation of a Supination External Rotation IV Trimalleolar Ankle Fracture

The Surgeon

Surgeon Name: Dr. Joshua A. Sebag DPM, AACFAS

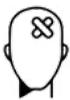Hospital: St. Lucie Medical Center, Port St. Lucie, Florida

Dr. Sebag is an Ankle and Foot surgeon with experience in complex foot and ankle injuries. He works at Coastal Orthopaedic & Sports Medicine Center in Stuart and Port St. Lucie, FL.

Introduction

Ankle fractures are amongst the most commonly encountered lower extremity injuries having a significant impact on quality of life and years lived with disability (YLD)⁽¹⁾. Reducing disability and increasing function are pillars of surgical treatment.

The Case



Patient Profile

The patient was a 61 year old female who presented to the emergency department with an inversion-type ankle injury which occurred while gardening in her yard. She reported immediate pain, noticed ankle deformity, and was unable to ambulate. She was splinted and brought to the ED via EMS where plain film radiographs revealed an unstable trimalleolar ankle fracture, with normal bone stock, and free of other injury. Her past medical history is consistent with anxiety, depression, and polycythemia. She was otherwise quite healthy, active, and frequently traveled out of the country as a dual citizen. Following closed reduction and posterior splinting, a non-contrast CT scan was ordered and she was admitted to our institution for fracture management.



Examination

Upon examination, the patient was in focal pain to the ankle with no other injuries to the proximal tibiofibular syndesmosis or lis franc apparatus. The soft tissue integument was normal and free of abrasion or fracture blisters. Neuroprotective sensation and vascular checks were within normal limits. An ice machine was placed on the limb to mitigate swelling and to optimize the patient for open reduction with internal fixation 48 hours later.

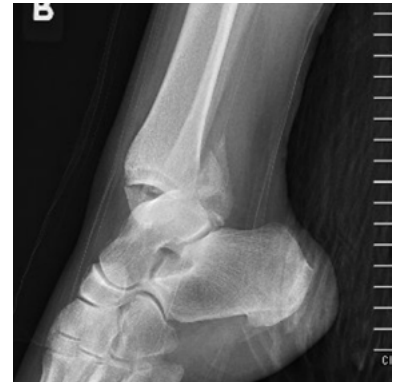
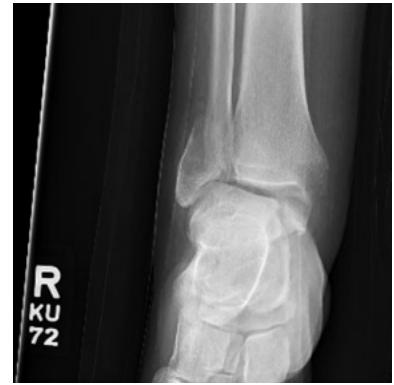
Imaging and Diagnosis

Post-reduction X-rays displayed a low Weber-B distal fibular fracture, and a large anterior colliculus dominate medial malleolar fracture. A posterior malleolar fracture comprising approximately 20% of the articular surface was also noted. CT Scan supported this diagnosis.

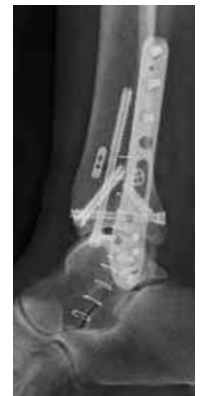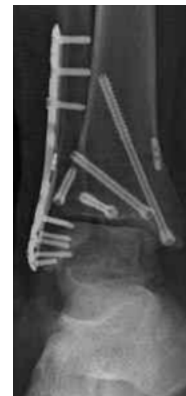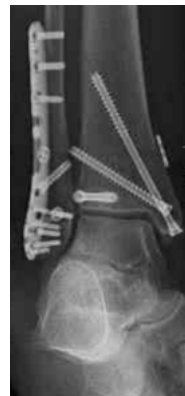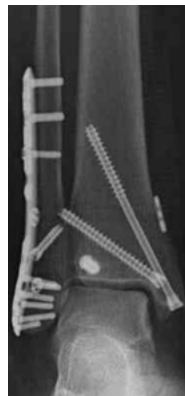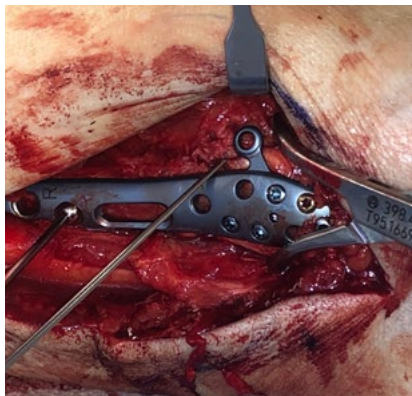Case Assessment

This healthy patient with normal bone stock and low comorbidities suffered a trimalleolar ankle fracture with posterior tibial lip involvement and PITFL/Syndesmosis instability. Advanced imaging was paramount in the preoperative planning and definitive fixation placement to maintain reduction of a complex osseous fracture which was performed in a stepwise approach. Surgical considerations included fibular nails, plate and screw internal fixation, and a combination of the two medical devices. Given the patients pre-injury activity level, overall health, normal soft tissue envelope, and our aligned goals for early weight bearing, a decision was made for ORIF with rigid internal fixation inclusive of plates and screws.



Surgical Treatment

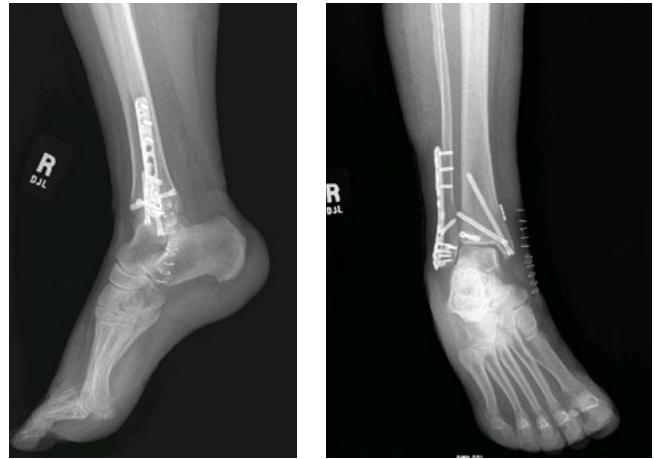Following regional block administration and supine positioning, a bump was positioned under the patient's ipsilateral hip. The Medartis Ankle Fracture set and 4.0 and 5.0 mm CCS screws were verified sterile. Following anatomic reduction using lobster claws and provisional wire fixation, the fibula was repaired first using a neutralization plate technique. The 3.5 cortical interfragmentary compression screw initially utilized did not provide adequate fixation and was replaced with a more robust 4.0 mm screw. This was bridged with an anatomic contoured 2.8/3.5 mm lateral malleolus locking plate with Wagstaffe tab. For additional distal tibial fixation, Headless 5.0 mm CCS screws were chosen to mitigate the tendency of screw migration during early weight bearing protocols. The medial malleolus was next fixated with a headless 5.0 mm CCS long thread screw. A fully threaded 5.0 mm CCS screw was then placed adjacent to this as a de-rotational screw. The posterior malleolous was next fixated using a posterior to anterior approach and a single short thread 5.0 mm CCS screw. Once verified with fluroscopy to be well positioned, syndesmosis stress maneuvers suggested uncertain residual instability, therefore a decision was made for flexible transyndesmotomic fixation. This was achieved using a dual button and non-absorbable suture style device. Layered closure was performed and a padded below knee splint applied.





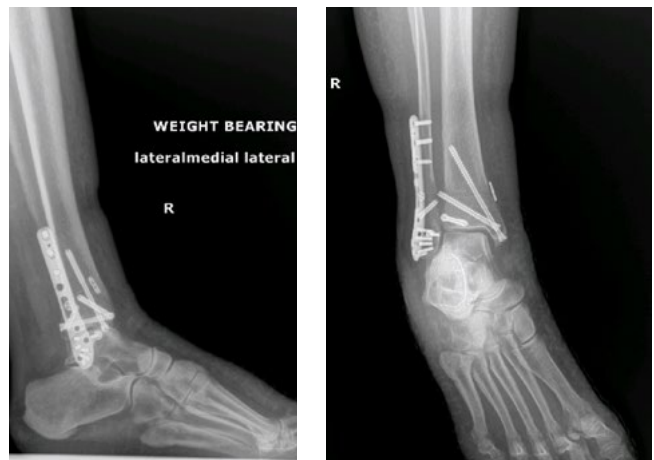Two Weeks Postoperative

At two weeks postoperative the splint and sutures were removed. A controlled ankle motion boot was dispensed, and the patient was instructed to begin passive and active ROM outside of the boot. Partial protected weight bearing was initiated at 50% body weight and increased by 25% each week thereafter with walker assist.



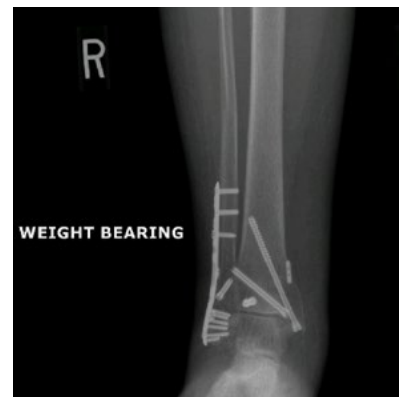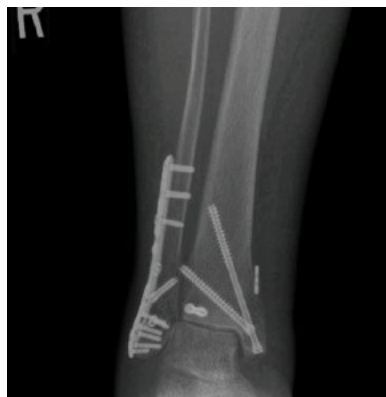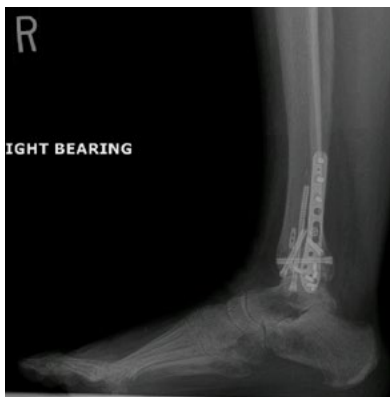Four Weeks Postoperative

X-rays taken at four weeks postoperative showed good alignment and adequate bone healing and patient was instructed to begin unassisted protected weightbearing in the boot. Self-directed physical therapy was encouraged, the patient was required to sleep in the boot for the first six weeks, and formal physical therapy was initiated at week 8.



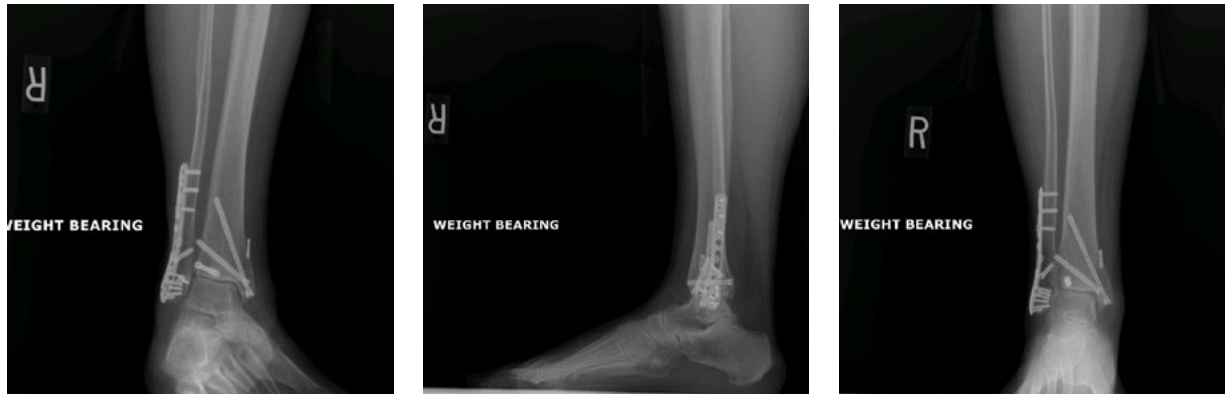Eight Weeks Postoperative

The eight-week postoperative x-rays showed sufficient healing to allow for slow weaning from the walking boot into a lace-up brace over two weeks. The patient was then allowed to gradually transition to full weight bearing with lace-up ankle brace in a supportive shoe. The ankle brace was discontinued at 16 weeks post injury and the patient fully resumed activities of daily living.



Six Month Postoperative

The six month postoperative x-rays reveal complete fracture trabeculation and healing, anatomic and congruent ankle alignment, and no evidence of hardware issue.



Conclusion

Complications due to traumatic injury, in particular those which are periarticular, segmented, or fragility fractures in a weight bearing limb require important treatment considerations in order to return the injured to early weight bearing.

The Medartis ankle fracture system, in conjunction with CCS 4.0 screws, allow a versatile combination of internal fixation in scenarios where precise screw placement is required and multi-joint preservation is key. With all the plate's holes providing axial variability, locking potential, and low profile Grade 4 titanium, the system allows confident implantation of hardware and empowers the surgeon due to freedom from fixed screw orientations. Additionally, flexible syndesmotic implants are compatible within the 3.5 mm plate screw holes. The system allows for accurate and precise placement of hardware, immediate stability, and reduction of the fracture fragments through thoughtful anatomic hardware design.

This patient was consented for this publication and continues to do well at >12 months post injury.



References

- 1) McPhail SM, Dunstan J, Canning J, Haines TP. Life impact of ankle fractures: qualitative analysis of patient and clinician experiences. *BMC Musculoskelet Disord.* 2012;13:224. doi:10.1186/1471-2474-13-224.

Disclaimer: This case report presents the outcome of an individual patient case and it does not imply any guarantee or warranty in regard to treatment success. A surgeon must always rely on her or his own professional clinical judgment when deciding whether to use a particular product when treating a particular patient. The professional must always comply with the individual product's Instructions For Use (www.medartis.com/documentation/instructions-for-use) as well as all laws and regulations. Medartis is not giving any medical advice. The devices may not be available in all countries due to registration and/or medical practices. All content – such as texts, video and pictures – was created by healthcare professional mentioned in the case report. For further questions, please contact your Medartis representative (www.medartis.com). This information contains products with CE and/or UKCA marking.
For US only: Federal law restricts this device to sale by or on the order of a physician.

© Medartis 2024. Everything herein is protected by copyright, trademarks and other intellectual property rights, as applicable, owned by or licensed to Medartis or its affiliates unless otherwise indicated. It is forbidden to redistribute, duplicate or disclose, anything herein, in whole or in part, without the prior written consent of Medartis.