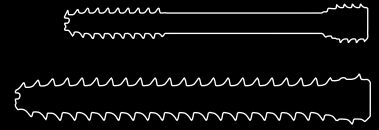


CASE REPORT



Scaphoid Non-union Fixation with CCS screw

The Surgeon

Ms Grainne Colgan

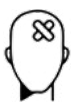Ms Grainne Colgan, Mater Misericordiae University Hospital, Dublin, Ireland who is an EBHS Trauma & Orthopaedic Surgeon. She specialises in hand and wrist trauma – paediatric and adult. Her subspecialty interest is Spasticity. She has a strong research, teaching and academic background, and has two higher degrees by research theses (MCh & MSc). She has numerous publications and book chapters.

Introduction

Although union rates are high (88% to 95%), delayed union and non-union can occur even in stable scaphoid fractures despite early, adequate immobilisation.¹

Use of cannulated compression screws alone in such cases have shown high union rates and reduced surgical morbidity and recovery time by avoiding more invasive open surgery and bone graft harvesting.²

The Case



Patient Profile

19-year-old male athlete, plays national sport at inter-county level. Right hand dominant. Hyper-extension injury to right wrist 27 weeks prior.



Clinical Findings

The patient was referred for specialist opinion 27 weeks post injury due to non-union. (Figure 1 & 2). His initial injury was an undisplaced waist of scaphoid fracture which had been managed in cast for 12 weeks but had not united. He had on-going pain in the wrist and was unable to play sport. Dorsiflexion was limited to 50°.



Preoperative Assessment

CT scan demonstrated a non-union, but no collapse/humpback deformity (Figure 3). There were no cystic changes and minimal sclerosis. The surgical options were discussed with the patient who wished to avoid iliac crest harvesting in order to have an early return to sport that season.

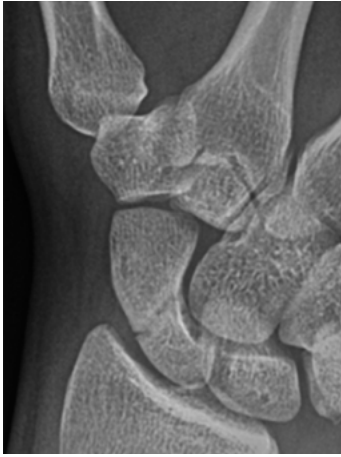


Figure 1

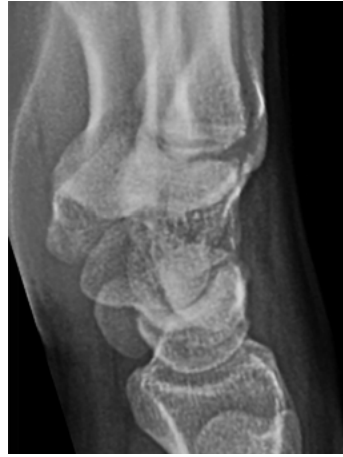

Figure 2

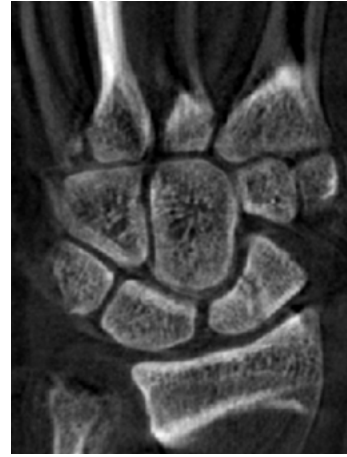

Figure 3



Surgical Treatment

Surgical treatment consisted of 3.0 mm CCS screw fixation through a mini-open dorsal approach to identify and protect EPL tendon.

The entry point for the screw is chosen to achieve a trajectory which is as perpendicular to the fracture line as possible, to optimise compression. A 1.1 mm K-wire was passed and position on AP, lateral and 2 oblique views were checked with fluoroscopy. Although the CCS screw is self-drilling and self-tapping - in this case as the proximal bone was extremely hard – it was drilled to the fracture line to stimulate healing.

It is important to choose the correct length and to monitor the fracture line on fluoroscopy as the screw is deployed to ensure compression is achieved – and not distraction. In this case we used a 22 mm screw (short thread length). The optimal length of screw is to have the threads in subchondral bone at either end to maximise purchase.



Postoperative Treatment

The wrist was immobilised for 4 weeks in cast, followed by physiotherapy rehabilitation to encourage and improve range of motion.

X-rays at 8 weeks showed healing and he had a pain-free wrist. Dorsiflexion was improved to 65° and palmar-flexion to 45° (Figures 4-6).

He returned to contact sport at 10 weeks and has remained pain free at 6 months follow up.

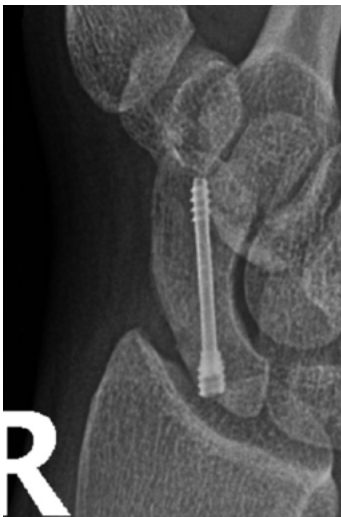

Figure 4

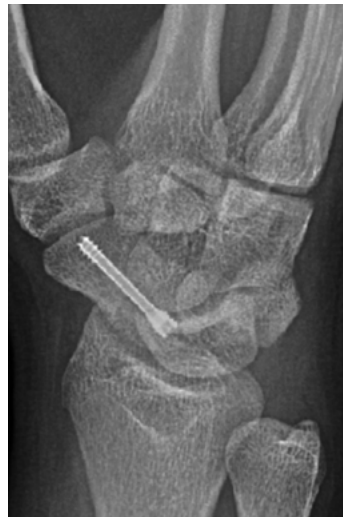

Figure 5

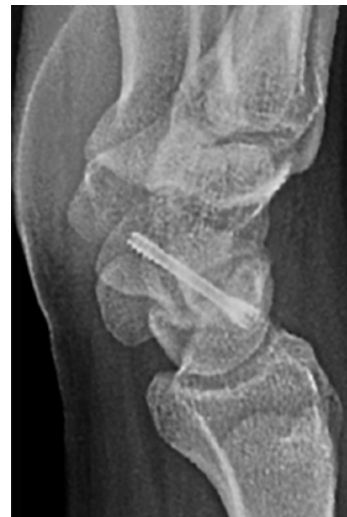

Figure 6



Conclusion

Without sufficient stability at the fracture site, micromotion may interrupt the fracture healing and result in non-union. Open treatment with bone graft is advocated for cases where there is bone loss +/- humpback deformity. Stable and well aligned non-unions may only require rigid fixation with compression to achieve union. Furthermore, drilling across the fracture site further helps to stimulate the fracture site.

In this case, union was achieved at 8 weeks to facilitate an early return to sport in a young athlete who was symptomatic.



References

- 1) Kawamura K, Chung KC. Treatment of scaphoid fractures and nonunions. J Hand Surg Am. 2008;33(6):988-997.
- 2) Saint-Cyr M, Oni G, Wong C, Sen MK, LaJoie AS, Gupta A. Dorsal percutaneous cannulated screw fixation for delayed union and nonunion of the scaphoid. Plast Reconstr Surg. 2011;128(2):467-473.

Disclaimer: This case report presents the outcome of an individual patient case and it does not imply any guarantee or warranty in regard to treatment success. A surgeon must always rely on her or his own professional clinical judgment when deciding whether to use a particular product when treating a particular patient. The professional must always comply with the individual product's Instructions For Use (www.medartis.com/documentation/instructions-for-use) as well as all laws and regulations. Medartis is not giving any medical advice. The devices may not be available in all countries due to registration and/or medical practices. All content – such as texts, video and pictures – was created by healthcare professional mentioned in the case report. For further questions, please contact your Medartis representative (www.medartis.com). This information contains products with CE and/or UKCA marking.
For US only: Federal law restricts this device to sale by or on the order of a physician.

© Medartis 2024. Everything herein is protected by copyright, trademarks and other intellectual property rights, as applicable, owned by or licensed to Medartis or its affiliates unless otherwise indicated. It is forbidden to redistribute, duplicate or disclose, anything herein, in whole or in part, without the prior written consent of Medartis.