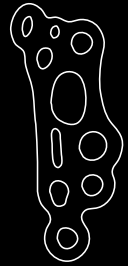


CASE REPORT



Modified Lapidus Fusion

The Surgeon

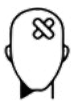Kar Teoh

Mr Teoh is a triple board certified Trauma and Orthopaedic surgeon with a special interest in Foot and Ankle surgery at Princess Alexandra Hospital, Harlow. He is also currently the clinical lead for trauma services for his trust. He did his higher surgical training in the Wales Deanery after completing his medical school and academic foundation programme in Edinburgh. His advanced Foot and Ankle training was based in Ysbyty Ystrad Fawr.

Introduction

First tarsometatarsal fusion (also known as Lapidus procedure) can provide a powerful correction of for a hypermobile, recurrent or severe hallux valgus deformity as it addresses the deformity proximally.¹⁾ Lapidus's original description involved fusing the base of first and second metatarsal as well. The Lapidus arthrodesis can be modified to fuse only the first tarsometatarsal joint (Modified Lapidus).¹⁾ Normally a period of immobilisation is required for this procedure.²⁾

The Case



Patient Profile

A fit and well 23-year-old lady presented with a symptomatic recurrence of her right hallux valgus deformity. She was previously diagnosed with bilateral Juvenile Hallux Valgus and had it surgically corrected with a chevron osteotomy during her adolescence. She was keen to have this re-corrected as she needed to be on her feet all day for work. She confirmed she has failed all conservative treatment. Weightbearing radiographs of her feet were obtained.



Clinical Findings / Preoperative Analysis

Her hindfoot was in physiological valgus with no signs of gastrocnemius tightness. Her previous scars were well healed but looked keloid in nature. There was an obvious hallux valgus deformity with medial skin irritation on her right. Her 1st MTPJ movement were pain free and well preserved. She had signs of hypermobility in her 1st TMTJ. Her Beighton score was 7/9. Her radiographs showed an increased intermetatarsal angle of 20 degrees and hallux valgus angle of 39 degrees. The metalwork in her right foot has previously been removed.

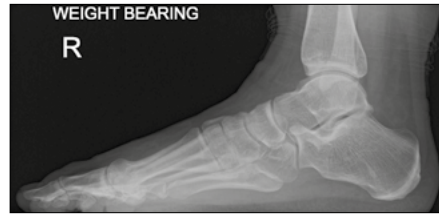

Figure 1

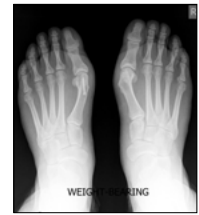
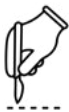
Figure 2



Surgical Treatment

A dorsomedial longitudinal skin incision is centered over the first TMT joint and extended as a medial incision to the level of the first MTP joint and the proximal phalanx. Care should be taken to protect the dorsal cutaneous nerves. Distal soft tissue release is an essential step to allow for correction of the IMA. It includes releasing the capsule, adductor tendon, lateral collateral ligament, and transverse metatarsal ligament lateral to the first metatarsal. Following this, the first TMT joint is exposed. Joint preparation is made with a saw blade as it is difficult to realign the joint by only removing the cartilage from the surface. The initial joint resection is performed on the first metatarsal articular surface border parallel to the first metatarsal base and perpendicular to the long axis of the first metatarsal bone. The resection is made taking only a small sleeve of subchondral bone to prevent shortening. The medial cuneiform articular resection is made perpendicular to the axis of the second metatarsal bone in the coronal plane, i.e. cutting a lateral wedge of the medial cuneiform. It is crucial to start the cuneiform cut inside the cuneiform cartilage area to avoid over shortening of the first ray. The wedge is performed biplanarly by removing more bone on the plantar side than dorsally; this helps plantarflexing the first ray during arthrodesis. Both arthrodesis surfaces are debrided and drilled down to healthy bleeding subchondral bone several times with a small drill bit. The deformity correction manoeuvre includes first metatarsal adduction, supination, and simultaneous maintenance of neutral plantarflexion, combined with axial compression of the MTP joint. Special attention should be given to correct the pronation of the first metatarsal which brings back the sesamoids to their anatomical articulations; this can be achieved with the assistant dorsiflexing the 1st MTP joint and applying supination, adduction, and plantarflexion with axial loading. The desired position is held temporarily by one K-wire. After confirmation with fluoroscopy, a cortical screw is inserted with a lag technique from dorsal to plantar and from the middle of the dorsum of the first metatarsal to the medial cuneiform to hold the position.

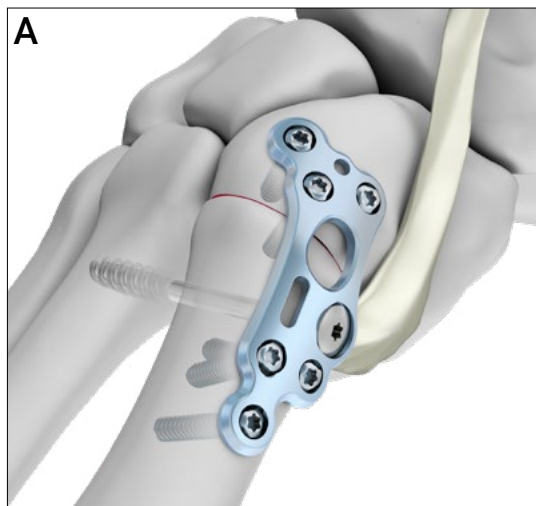


Figure 3

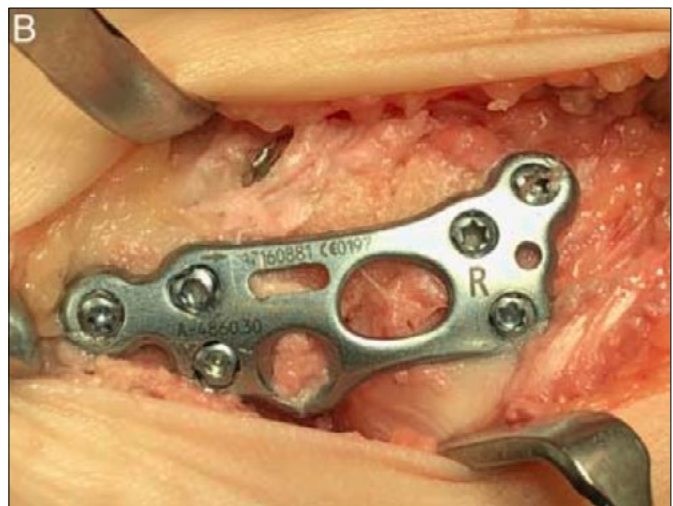
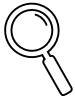
Figure 4



Intraoperative Findings

The Medartis anatomical dorsomedial Lapidus plate fitted well and avoided the tibialis anterior tendon. Screws are placed over the proximal cuneiform plate holes first. A trilock compression screw is placed distally in the metatarsal metaphysis in the dynamic slot to provide further compression at the arthrodesis side. The remaining screws are inserted into the plate with a combination of locking and non-locking screws. The plate also allows the option of inserting olive k-wires through plate holes and achieving further compression at the arthrodesis site.

A first web space compression stress test was performed following the modified Lapidus arthrodesis. As there was no increase in IMA, an original Lapidus screw was not required (base of 1st and 2nd metatarsal fusion).

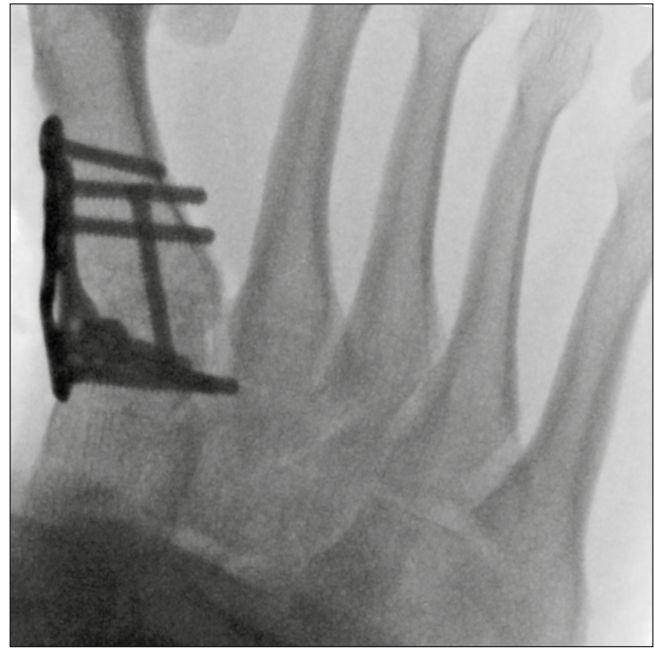

Figure 5



Postoperative treatment

She was immobilised in a plaster of paris backslab for the first two weeks to allow the wound to heal. At 2-weeks post operation, she was allowed to start early partial weight bearing with a walking boot. After 6 weeks, she was allowed to progress to full weight bearing.

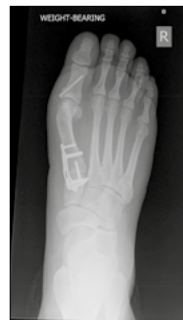

Figure 6

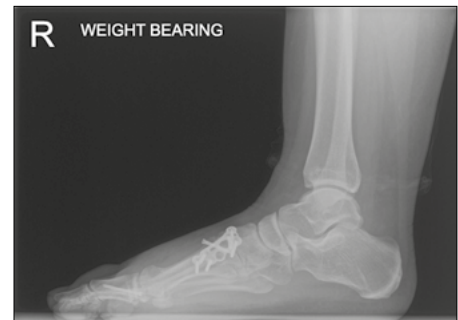

Figure 7



Conclusion

Current designs of Lapidus plates allow the plates to be placed dorsally, medially or plantar. Hypothetically, to resist these forces, we should consider 90-90 plating (ie, an arrangement of two plates placed at a relative 90 degrees angle medially and dorsally) with a medial plate to resist the transverse mobility and a dorsal plate to withstand sagittal instability. Medartis anatomic dorsomedial plate has been designed to improve the success of the Lapidus arthrodesis based on the above concept. The design also provides the flexibility to perform the original Lapidus if required. There is no hardware irritation or impingement on the anterior tibialis tendon and allows easy placement of the crossing lag screw. The construct is strong enough to allow early protected weightbearing.



References

- 1) Alshalawi, S, Teoh, KH; Alrashidi, Y, Galhoum, A, Wiewiorski, M, Herrera-Perez, M, Barg, A, Valderrabano, V. Lapidus Arthrodesis by an Anatomic Dorsomedial Plate. *Techniques in Foot & Ankle Surgery* 19(2):p 89-95, June 2020. | DOI: 10.1097/BTF.0000000000000231
- 2) Blitz NM, Lee T, Williams K, Barkan H, DiDimenico LA. Early weight bearing after modified lapidus arthrodesis: a multicenter review of 80 cases. *J Foot Ankle Surg.* 2010;49(4):357-362. doi:10.1053/j.jfas.2010.04.014

Disclaimer: This case report presents the outcome of an individual patient case and it does not imply any guarantee or warranty in regard to treatment success. A surgeon must always rely on her or his own professional clinical judgment when deciding whether to use a particular product when treating a particular patient. The professional must always comply with the individual product's Instructions For Use (www.medartis.com/documentation/instructions-for-use) as well as all laws and regulations. Medartis is not giving any medical advice. The devices may not be available in all countries due to registration and/or medical practices. All content – such as texts, video and pictures – was created by healthcare professional mentioned in the case report. For further questions, please contact your Medartis representative (www.medartis.com). This information contains products with CE and/or UKCA marking.
For US only: Federal law restricts this device to sale by or on the order of a physician.

© Medartis 2024. Everything herein is protected by copyright, trademarks and other intellectual property rights, as applicable, owned by or licensed to Medartis or its affiliates unless otherwise indicated. It is forbidden to redistribute, duplicate or disclose, anything herein, in whole or in part, without the prior written consent of Medartis.