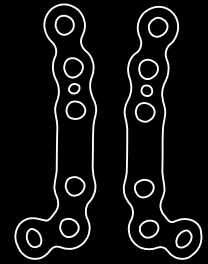


CASE REPORT



Treatment of Hallux valgus using a plantar TMT-1 fusion plate

The Surgeon

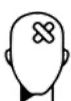PD Dr. Christian Plaass

After completing his studies at the Johannes Gutenberg University in Mainz, PD Dr. Christian Plaass completed his specialist training in orthopaedics and traumatology of the musculoskeletal system (FMH) in Switzerland. In addition to his orthopaedic training and work in hand surgery, he gained his foot surgery knowledge from Prof. Dr. B. Hintermann in Liestal and Prof. Dr. Dr. V. Valderrabano in Basel. In 2009, PD Dr. Plaass moved to the Orthopaedic Clinic of the Hannover Medical School in Annstift, where he has been a senior physician since February 2014. PD Dr. Plaass is a member of the D.A.F. and the EFAS. Dr. Plaass holds the D.A.F. certificate for foot surgery and has been a regular instructor in the D.A.F. course system since 2009. He is member of the REC of the International Bone Research Association and of Qualitätskreis Knorpel-Repair & Gelenkerhalt e.V. – German chapter of the ICRS. He is Co-editor of Fuss- und Sprunggelenk, Journal of the German Foot and Ankle society (D.A.F.). Dr. Plaass is scientifically active in the field of foot surgery and is an active speaker at national and international congresses.

Introduction

Hallux valgus is the most common forefoot deformity. Depending on the amount of deformity and associated pathologies different treatment options exist. The modified Lapidus procedure addresses the origin of the pathology and allows the correction of all three dimensions of the deformity. Using a plantar plate has shown to be a safe procedure with increased biomechanical stability and less soft-tissue irritation, than conventional plating.

The Case



Patient Profile

A 58 year old active patient complained of pain on the Callus due to a significant Hallux valgus (HV) deformity. As a former professional ballet dancer and ballet director he is very sportive and functional demanding. During his active career several traumas happened to the hallux, but the joint is pain-free.



Clinical Findings/Preoperative Analysis

Clinical findings revealed a typical hallux valgus deformity and free range of motion of the MTP-1. Despite hypermobility of the 1st ray, there was no Metatarsalgia. The radiological findings (Figures 1-3) showed the widened intermetatarsal space, Hallux valgus deformity with Hallux valgus interphalangeus. A small (asymptomatic) ossicle is in the medial capsule, due to the preoperative trauma. Pronation of the MTP-1 is found on the sesamoid view.

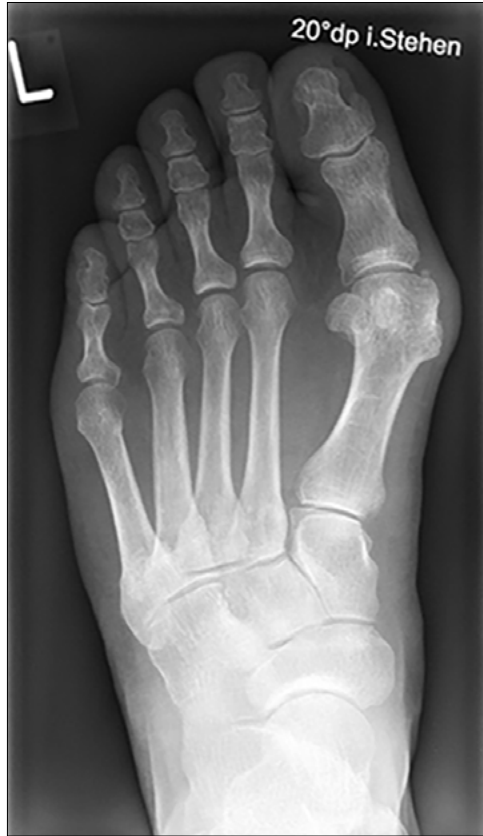

Figure 1

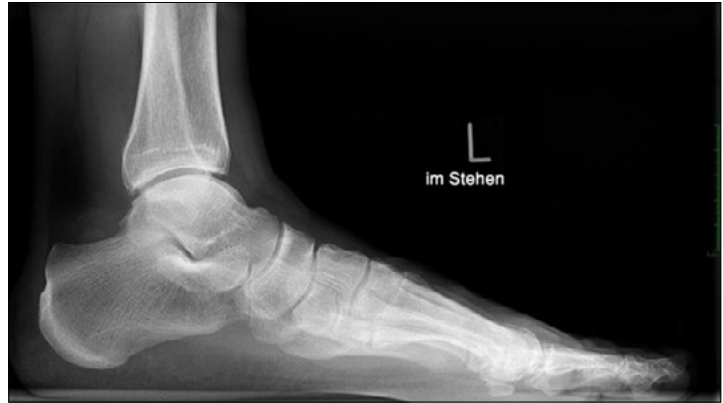

Figure 2

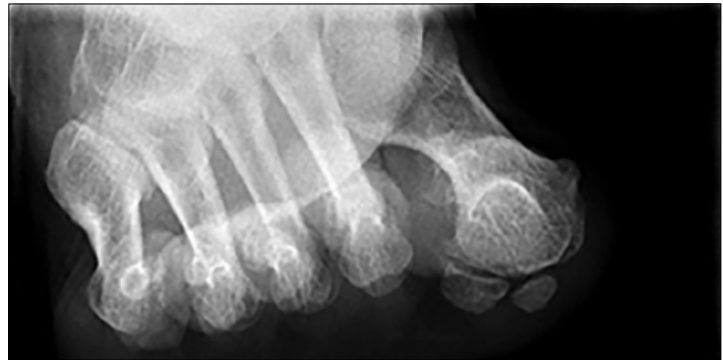
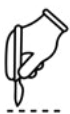
Figure 3

Figures 1-3: Preoperative full weight bearing foot d.p. (Fig. 1) lateral (Fig. 2) and sesamoid view (Fig. 3). X-rays show a significant Hallux valgus with an increased Intermetatarsal I-II angle of 18° , Pronation of the First ray and a positive round sign.



Surgical Treatment

The patient is in supine position and a tight tourniquet is applied. A straight medial incision from the proximal phalanx of the Hallux to the medial cuneiforme mediale is performed. The incision is done in line with the 1st rays bones. During preparation care is taken not to damage the veins and the soft tissues are mobilized dorsally. The MPT-1 capsule is opened in a Y-shaped manner. The Hallux is mobilized using a McGlamry elevator until a varisation of the hallux is possible.

Then the TMT-1 joint is exposed and by protection the surrounding soft tissues with retractors, the cartilage is removed from the Metatarsal and cueneiform. No wedge resection is performed. Reposition is achieved by an abduction, supination move, as the metatarsal follows the position of the great toe. The position is temporarily fixed with a K-wire and radiologically checked. The round-sign, the DMAA, the Hallux valgus angle, Intermetatarsal angle and sesamoid position are checked.

When a sufficient reduction is achieved a Medartis CCS 5.0 screw is used to fix the arthrodesis. In hard bone a previous countersinking is performed. A possible rotation of the first ray during insertion of the screw is checked and corrected if necessary.

A Hook-test is performed- a horizontal traction is applied and any opening of the intermetatarsal / -cuneiform space is evaluated. In case of instability an additional intermetatarsal or intercuneiform stabilization is done.

The plantar plate is applied after the muscle of the abductor hallucis muscle is mobilized. A vessel going plantarly into the base of the TMT-1 has to be coagulated regularly. The plate is placed that it does not interfere with the tibialis anterior tendon insertion. The plate is then fixed proximal and distally.

An Akin osteotomy is performed regularly and fixed with a suture.

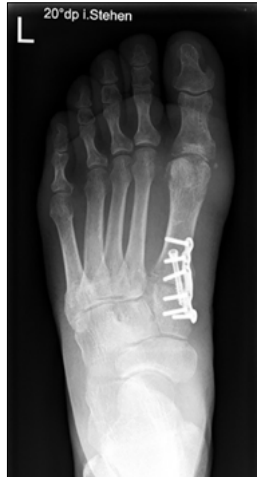

Figure 5

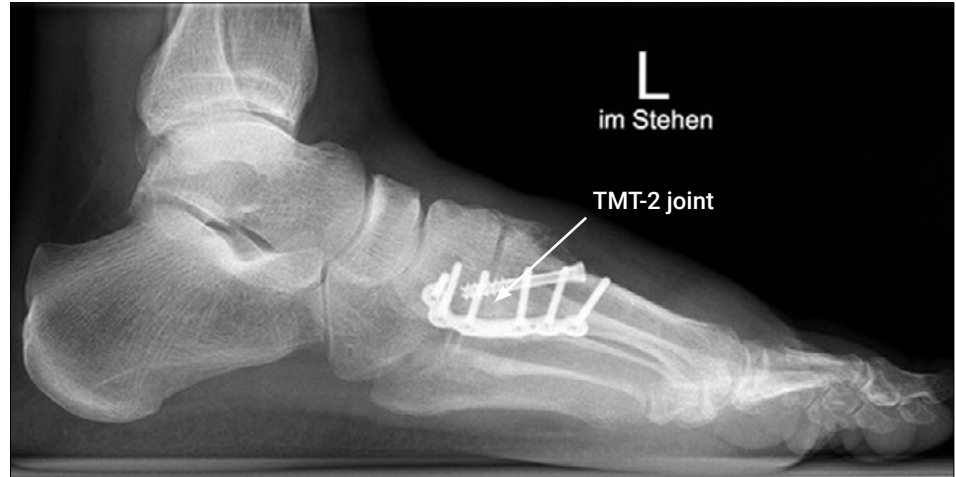

Figure 6

Figures 5 & 6: 6 weeks postoperative full weight bearing x-rays d.p. (Fig. 5) and lateral (Fig. 6) show a corrected intermetatarsal angle and good position of the toe. The Metatarsal head shows no round-sign any more and the sesamoids are centered, due to 3-Dimensional correction of the Metatarsal 1. The plantar plate allows early weight bearing, due to the excellent soft-tissue coverage, hardware removal is hardly ever necessary.



Postoperative Treatment

A walker is applied, and partial weight bearing applied for 6 weeks. Lymphatic drainage is done and physiotherapy for MTP-1 mobilization.

After 6 weeks a radiograph (Figure 5 & 6) is performed, and full weight bearing allowed.



Conclusion

TMT-1 fusion for Hallux valgus treatment is powerful and safe technique to correct the deformity. Due to the muscle-belly covering the plate, hardware removal is usually not necessary.

Disclaimer: This case report presents the outcome of an individual patient case and it does not imply any guarantee or warranty in regard to treatment success. A surgeon must always rely on her or his own professional clinical judgment when deciding whether to use a particular product when treating a particular patient. The professional must always comply with the individual product's Instructions For Use (www.medartis.com/documentation/instructions-for-use) as well as all laws and regulations. Medartis is not giving any medical advice. The devices may not be available in all countries due to registration and/or medical practices. All content – such as texts, video and pictures – was created by healthcare professional mentioned in the case report. For further questions, please contact your Medartis representative (www.medartis.com). This information contains products with CE and/or UKCA marking.
For US only: Federal law restricts this device to sale by or on the order of a physician.

© Medartis 2024. Everything herein is protected by copyright, trademarks and other intellectual property rights, as applicable, owned by or licensed to Medartis or its affiliates unless otherwise indicated. It is forbidden to redistribute, duplicate or disclose, anything herein, in whole or in part, without the prior written consent of Medartis.