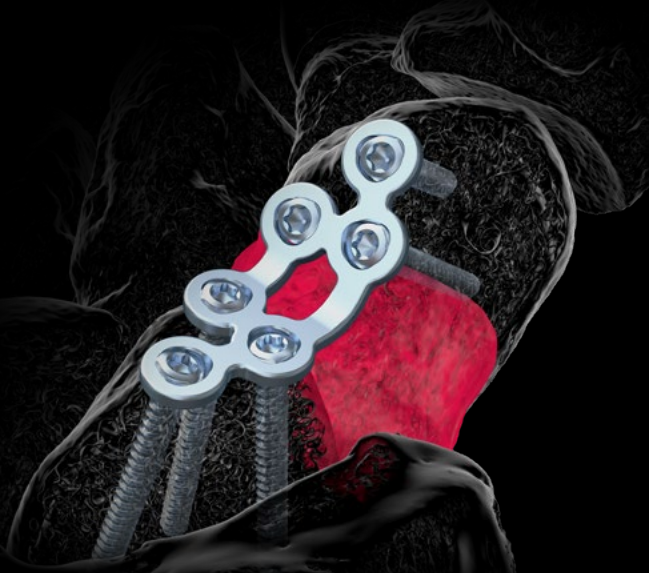



CASE REPORT



Case Study Scaphoid Plate: Athlete's Scaphoid Non-Union

The Surgeon

Dr. Pascal Hannemann

Hospital: Maastricht University Medical Center

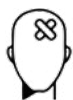Dr. Hannemann is a European Board of Hand Surgery certified hand and wrist surgeon. He works at the hand unit of the Maastricht University Medical Center. He is particularly interested in posttraumatic hand and wrist pathology. He is the author of many international scientific publications and book chapters, speaker and instructor in several national and international courses, and director of the national course on hand and wrist surgery for upcoming board-certified trauma surgeons in the Netherlands.

Introduction

A common complication of scaphoid fractures is non-union. Especially fractures that are initially missed and consequently not adequately treated are at risk for developing non-union. Untreated non-union may lead to a carpal collapse in a significant number of cases and result in progressive degenerative arthritis of the wrist and hand.^{1,2}

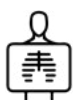Adequate treatment of scaphoid non-union is therefore essential. Here we describe the treatment of a scaphoid non-union with a Medartis APTUS Hand 1.5 Trilock scaphoid plate, together with an autologous bone graft from the ipsilateral iliac wing.

The Case



Patient Profile

20-year-old female athlete, semi-professional handball player. Right dominant. Fell on an outstretched left hand in October 2019 during a handball match. At the initial presentation at another hospital, no scaphoid fracture was diagnosed.



Clinical Findings / Preoperative Analysis

The patient presented at our centre 9 months after the initial event with persistent pain and functional deficit of her left wrist and hand. Flexion / extension of her left wrist was 30-0-60. Dynamometer showed 35% strength in her left wrist, when compared to the uninjured, contralateral side. Additional imaging showed a clear non-union of a left scaphoid waist / proximal pole fracture with osteolysis (figure 1).

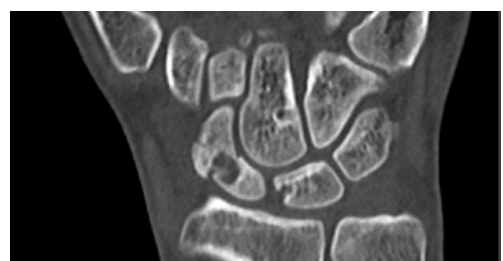


Figure 1

The sagittal images show osteolysis and non-union just at the transition between waist and proximal pole (figure 2). The preoperative MRI scan shows the non-union with signs of avascularity of the waist and proximal pole (figure 3).

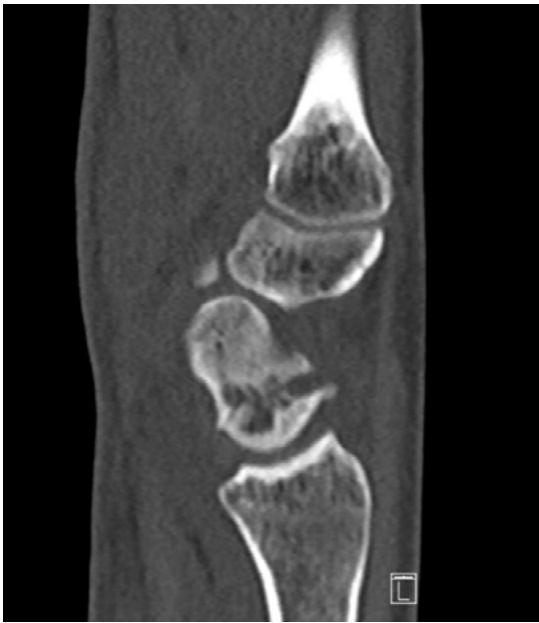

Figure 2

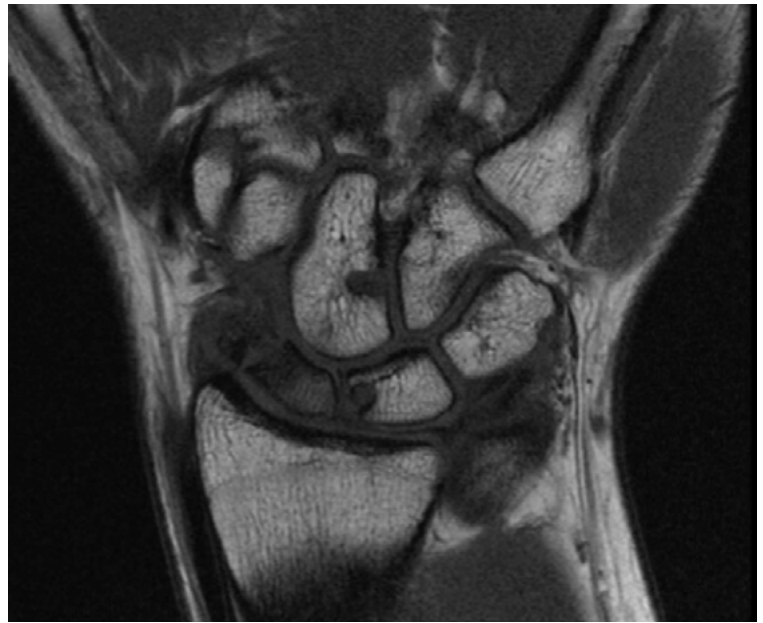


Figure 3



Surgical Treatment

Surgical treatment consisted of extensive debridement of the scaphoid non-union, correction of alignment of the scaphoid, and fixation of the nonunion with a Medartis APTUS Hand 1.5 TriLock scaphoid plate.

The defect after debridement was filled with a cancellous bone graft from the ipsilateral iliac crest after a minimally invasive approach. Extensive debridement of the non-union is advised.

Attention is paid to the position of the screws in the proximal pole, in a way that at least 2 but preferably 3 screws are placed in the proximal part of the scaphoid.

In this particular case, an additional 1.2 screw was placed in the proximal part of the scaphoid to fix an additional cortical fragment.

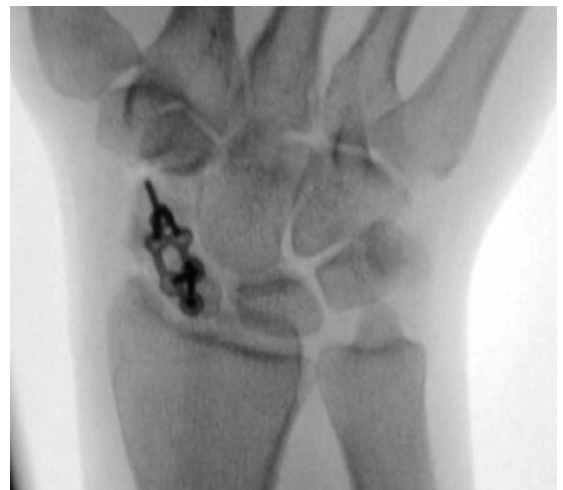

Figure 4

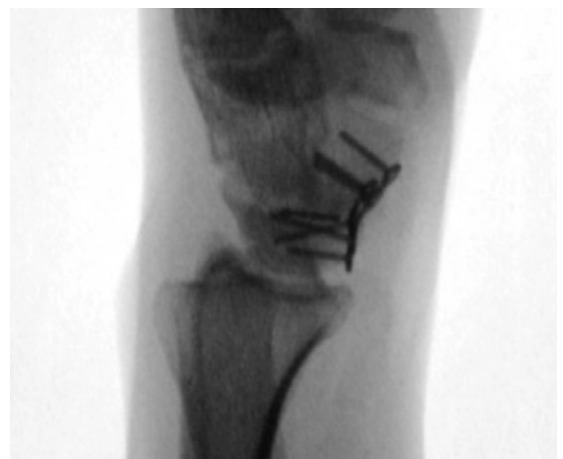

Figure 5



Postoperative Treatment

For wound healing purposes, the wrist was only immobilized for 10 days postoperatively. Afterwards, full functional use of the hand was encouraged.

After six weeks postoperatively, weight lifting of more than 2 kg was allowed. At 4 months postoperatively, a CT scan confirmed complete union of the scaphoid non-union with a normal anatomical appearance of the scaphoid (figures 6 and 7).

The plate was removed 5 months postoperatively to improve functional outcome. The patient had full functional recovery after removal of the plate with flexion / extension of 80-0-70 and grip strength returning to 95% of the uninjured contralateral side. Afterwards, she participated again fully as a semi-professional handball player.

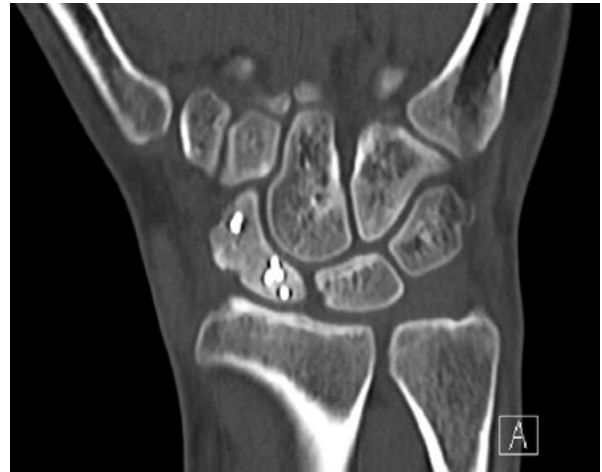

Figure 6

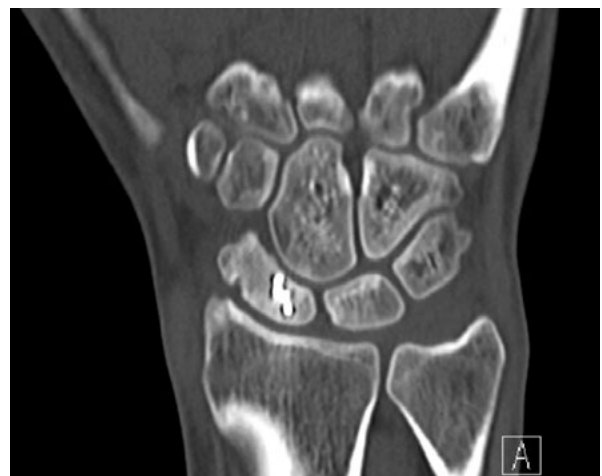

Figure 7



Conclusion

Successful treatment of a symptomatic scaphoid non-union in a young semi-professional athlete with the preferred technique of plate fixation and cancellous bone insertion. Due to its superior interfragmentary stability, the plate provides optimal circumstances for healing of all types of scaphoid non-unions. However, plate removal is advised in a significant number of cases due to possible impingement of the plate against the volar rim of the distal radius after healing of the scaphoid non-union.^{1,2}



References

- 1) Schormans PMJ, Kooijman MA, Ten Bosch JA, Poeze M, Hannemann PFW. Mid-term outcome of volar plate fixation for scaphoid nonunion. *Bone Joint J.* 2020;102-B(12):1697-1702. doi:10.1302/0301-620X.102B12.BJJ-2019-1160.R3
- 2) Schormans PMJ, Brink PRG, Poeze M, Hannemann PFW. Angular Stable Miniplate Fixation of Chronic Unstable Scaphoid Nonunion. *J Wrist Surg.* 2018;7(1):24-30. doi:10.1055/s-0037-1603202

Disclaimer: This case report presents the outcome of an individual patient case and it does not imply any guarantee or warranty in regard to treatment success. A surgeon must always rely on her or his own professional clinical judgment when deciding whether to use a particular product when treating a particular patient. The professional must always comply with the individual product's Instructions For Use (www.medartis.com/documentation/instructions-for-use) as well as all laws and regulations. Medartis is not giving any medical advice. The devices may not be available in all countries due to registration and/or medical practices. All content – such as texts, video and pictures – was created by healthcare professional mentioned in the case report. For further questions, please contact your Medartis representative (www.medartis.com). This information contains products with CE and/or UKCA marking.
For US only: Federal law restricts this device to sale by or on the order of a physician.

© Medartis 2024. Everything herein is protected by copyright, trademarks and other intellectual property rights, as applicable, owned by or licensed to Medartis or its affiliates unless otherwise indicated. It is forbidden to redistribute, duplicate or disclose, anything herein, in whole or in part, without the prior written consent of Medartis.