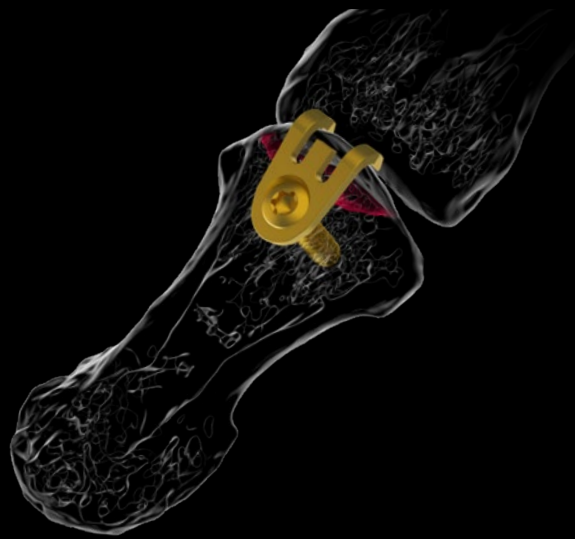

## CASE REPORT



# Fixation of Mallet Fracture with APTUS 1.2 / 1.5 Hook Plate

## The Surgeon

**Helen Abel M.D., associate professor**

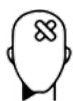**Hospital: Klinikum rechts der Isar, Technical University Munich**

Dr. Abel is a specialist for hand surgery. Her practice specializes in surgery for all aspects of the hand and upper limb. She has been trained at a large university hospital in Munich, the Klinikum rechts der Isar, Technical University Munich. Due to her expertise, she is a speaker at national and international congresses, an instructor for hand surgery workshops and a consultant for medical device companies.

## Introduction

Avulsion fractures of the distal phalangeal base comprising the insertion of the extensor tendon are called mallet fingers.<sup>1</sup> Depending on the fragment size and dislocation, surgery can be indicated.<sup>1</sup> Several surgical treatment options have been tried during the past decades. Data concerning the use of a hook plate are promising.<sup>2</sup>

## The Case



### Patient Profile

A 29-year-old man injured the right middle finger of his dominant hand rebounding a basketball. He was right hand dominant, nonsmoker and working as a landscape gardener. His medical history was empty with no preexisting illnesses.



### Clinical Findings / Preoperative Analysis

His finger was swollen and painful, especially over the distal interphalangeal (DIP) joint. There was no active extension but a 35° droop at the DIP. Radiographs of the finger revealed a dislocated fracture involving 40% of the dorsal articular surface of the distal phalanx, displaced more than 2 mm, with normal alignment of the volar part of the joint, no subluxation (Figure 1, 2).

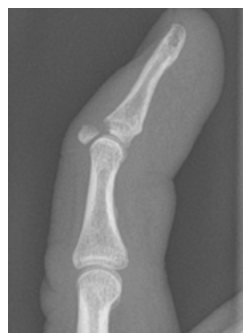

Figure 1

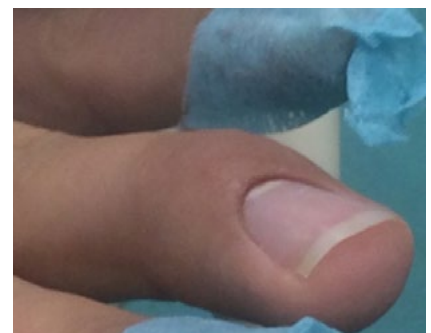


Figure 2



### Surgical Treatment

Surgery was performed within few days after trauma. We performed an open reduction and plate fixation under digital block anesthesia and a digital tourniquet. The surgical approach was through a V incision centered over the fracture. Fracture ends were curetted and cleaned and the fracture was reduced. Using the dedicated holding instrument, a 0.6-mm thin hook plate was placed with the hook passing through the terminal tendon to capture the dorsal edge of the articular fragment. After predrilling, a 1.5 mm cortical screw was used for securing the plate to the shaft of the distal phalanx. The wound was closed (figure 3).

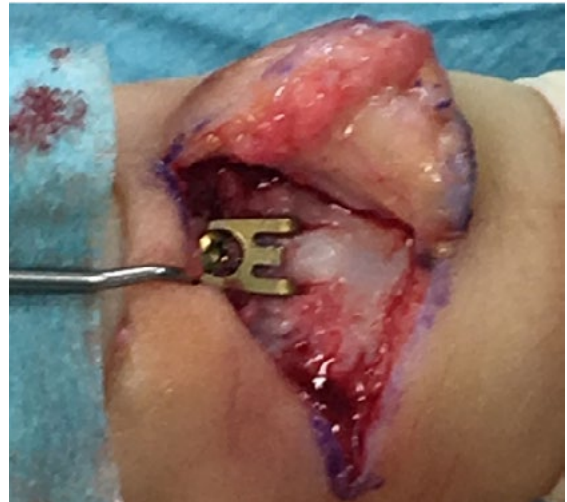


Figure 3



### Postoperative Treatment

Postoperative X-rays of the finger were obtained. The finger was placed in a mallet orthosis which immobilizes the DIP and allows movement in the PIP for 6 weeks. Passive/active range of motion exercises were introduced at the third week following surgery. Weightbearing was introduced after 6 to 8 weeks.

At the latest follow-up 3 months after surgery, the patient was pain-free, had regained full function and had returned to the same level of physical activity as prior to the injury. Follow-up radiographs revealed anatomic fracture union. We recommend plate removal after 12 weeks the earliest (figure 4).

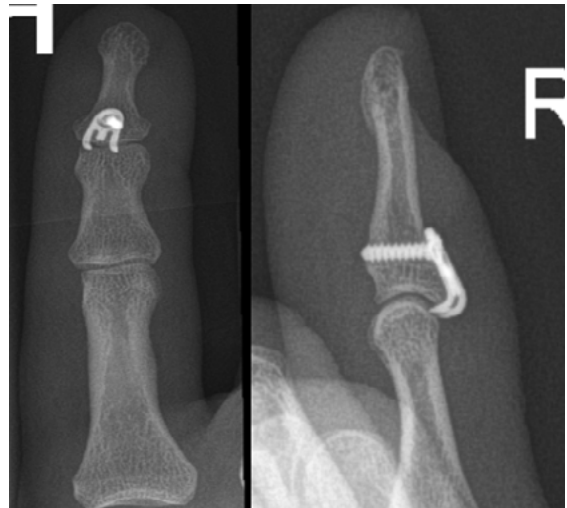


Figure 4



### Conclusion

The hook plate is an adequate and safe implant for treatment of mallet fingers. It is especially suitable for multiple fractured fragments when a screw fixation is not possible. Moreover, the fragment is "buttressed" while the fixation screw is kept away from the fractured area. Surgery is fast and easy and the complication rate is low. However, special care needs to be bestowed on the nail bed preparation to avoid nail growth problems. Apart from that, the plate needs to be removed almost always as patients are uncomfortable when there is pressure on it.



### References

- 1) Vester H, Schul L, von Matthey F, Beirer M, van Griensven M, Deiler S. Patient satisfaction after hook plate treatment of bony avulsion fracture of the distal phalanges. *Eur J Med Res.* 2018;23(1):35. Published 2018 Jul 20. doi:10.1186/s40001-018-0332-y
- 2) Wang WC, Hsu CE, Yeh CW, Ho TY, Chiu YC. Functional outcomes and complications of hook plate for bony mallet finger: a retrospective case series study. *BMC Musculoskelet Disord.* 2021;22(1):281. Published 2021 Mar 16. doi:10.1186/s12891-021-04163-2

Disclaimer: This case report presents the outcome of an individual patient case and it does not imply any guarantee or warranty in regard to treatment success. A surgeon must always rely on her or his own professional clinical judgment when deciding whether to use a particular product when treating a particular patient. The professional must always comply with the individual product's Instructions For Use ([www.medartis.com/documentation/instructions-for-use](http://www.medartis.com/documentation/instructions-for-use)) as well as all laws and regulations. Medartis is not giving any medical advice. The devices may not be available in all countries due to registration and/or medical practices. All content – such as texts, video and pictures – was created by healthcare professional mentioned in the case report. For further questions, please contact your Medartis representative ([www.medartis.com](http://www.medartis.com)). This information contains products with CE and/or UKCA marking.  
For US only: Federal law restricts this device to sale by or on the order of a physician.

© Medartis 2024. Everything herein is protected by copyright, trademarks and other intellectual property rights, as applicable, owned by or licensed to Medartis or its affiliates unless otherwise indicated. It is forbidden to redistribute, duplicate or disclose, anything herein, in whole or in part, without the prior written consent of Medartis.