

# CASE REPORT

## DRUJ Malalignment and dynamic impaction

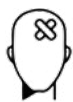### The Surgeon

Philipp Honigmann is a hand specialist who heads the Hand and Peripheral Nerve Surgery unit at the Cantonal Hospital Baselland. He is also the co-leader of the Swiss Medical Additive Manufacturing Research Group (Swiss MAM) at the University of Basel's Department of Biomedical Engineering. Dr. Honigmann additionally leads the 3D Print Lab at the Cantonal Hospital Baselland's Department of Orthopaedics and Traumatology. His expertise lies in reconstructive hand surgery, particularly carpal surgery, utilizing patient-specific 3D-printed guides and prosthetics. His research focuses on the use of 3D-printed applications in hand surgery and 4D-CT analysis of carpal kinematics post-carpal bone replacement in collaboration with the Department of Biomedical Engineering and Physics at the Amsterdam UMC, University of Amsterdam.

### Introduction

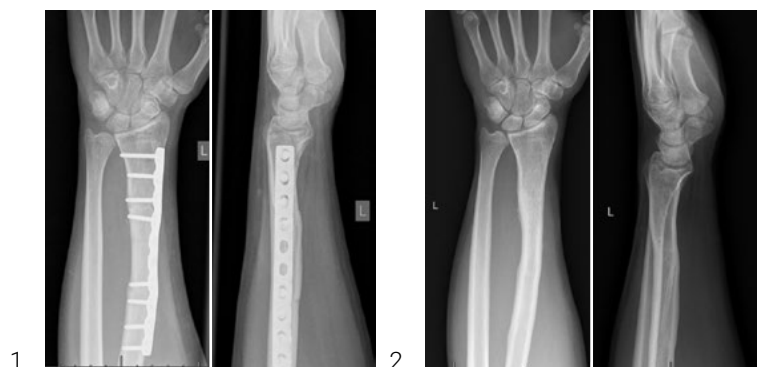The Distal Radio-Ulnar Joint (DRUJ) together with the Proximal Radio-Ulnar Joint (PRUJ) allows for forearm rotation. Osseous congruency (anatomy of the sigmoid notch and ulna head) provides 20% of the stability. The main stability is provided by soft tissue, especially by static stabilizers, the palmar and dorsal radioulnar ligaments. Primary stability is provided by the osseous anatomy of the sigmoid notch and the head of the ulna.<sup>1</sup>

### The Case



#### Patient Profile

28-year-old patient with ulnar carpal pain and lack of supination in the left wrist. He had an osteotomy of the distal radius shaft after a malunited distal radius fracture 10 years ago. After being pain free for 8 years, the pain progressively evolved and worsened during climbing as well as during compression of the wrist.



Figures 1–2: Pre-operative situation; 10 years ago, before (Figure 1) and after removal of material (Figure 2)



### Clinical Findings

Healthy and physically very fit young man. Lack of supination of 20°. Pain during ulnar carpal compression. Positive chair lift-off test. No other pathological findings.



### Preoperative Assessment

Corrective osteotomy was planned according to the mirrored contralateral healthy side and a guide was designed. In addition, a simulation of the postoperative situation using distance mapping was performed.

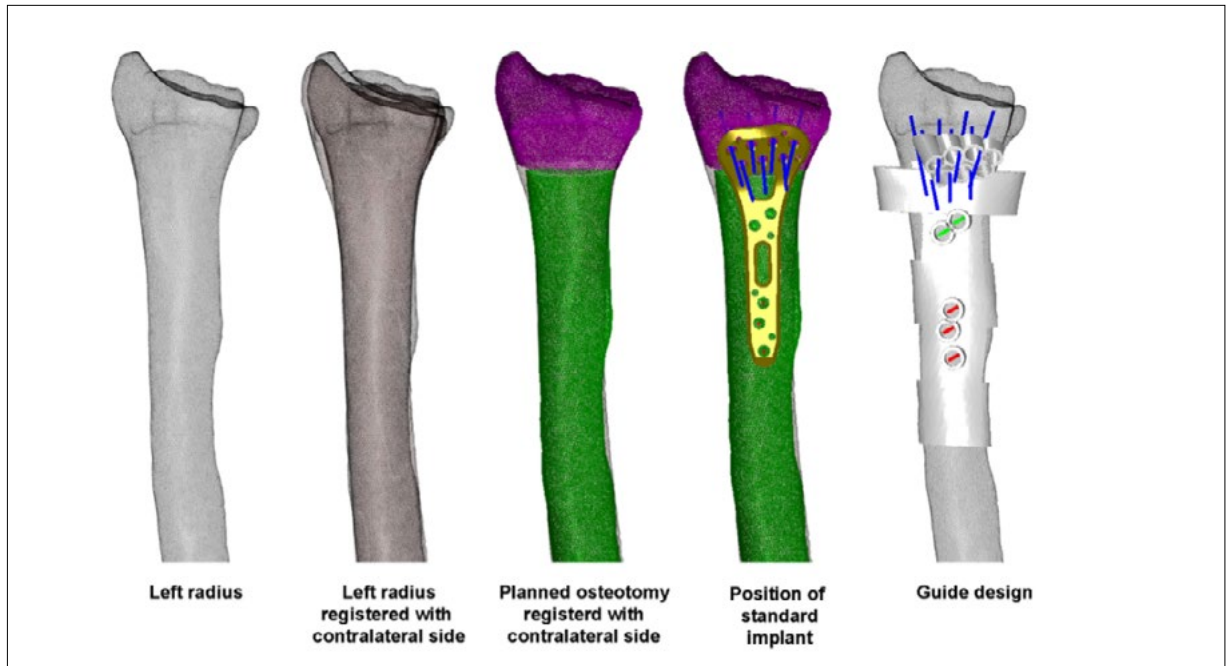


Figure 3: Corrective osteotomy planning

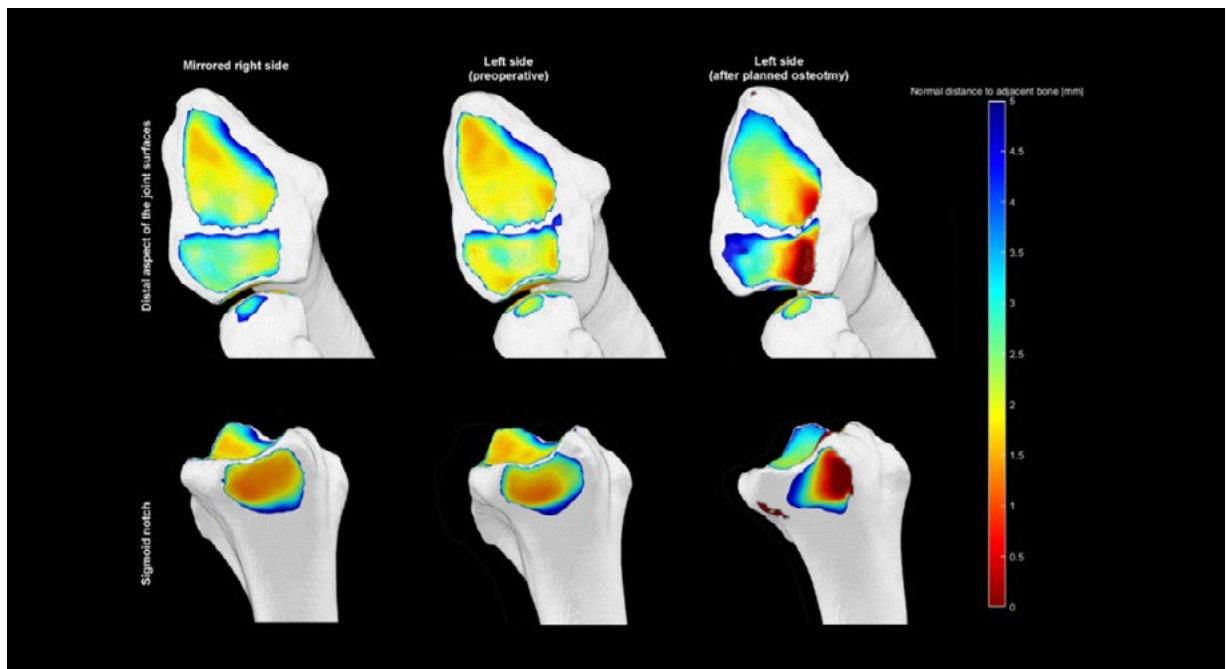


Fig 4: Simulation of the postoperative situation using distance mapping (dark red = 0 mm and dark blue  $\geq$  5 mm distance). The dark red area indicates contact of the bones (ulna in the dorsal sigmoid notch and lunate in the lunate fossa) which corresponds to a dorsal malposition of the ulna and lunate.

Based on the findings during the preoperative planning phase including 3D-simulation of the DRUJ compared with the mirrored contralateral side, it was decided to shorten and de-rotate the ulna instead of lengthening and rotating the radius. Guides were designed to perform the shortening osteotomy and de-rotation.

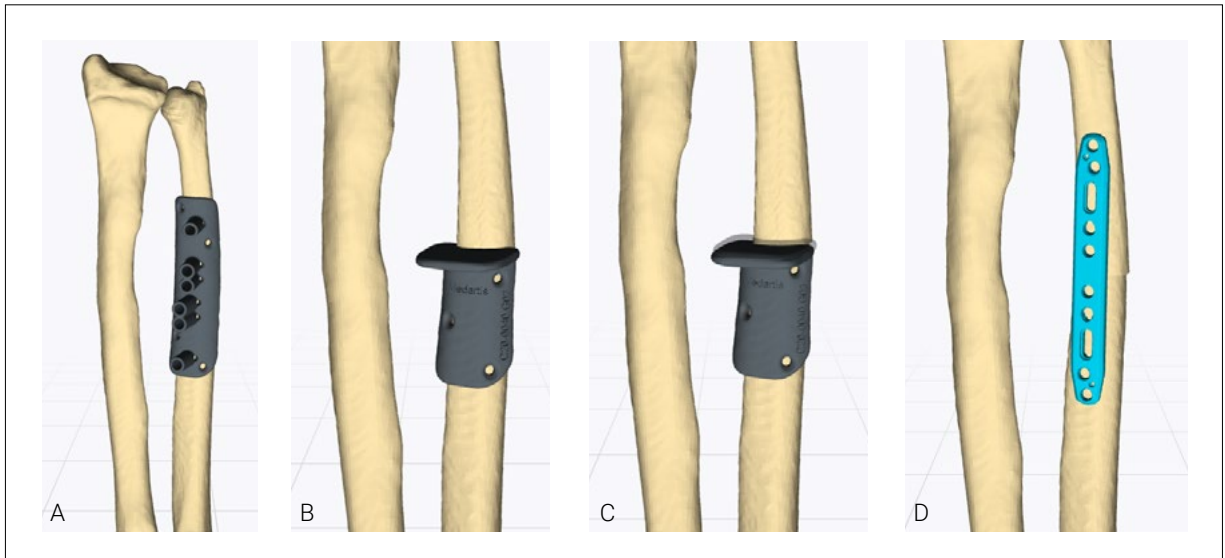
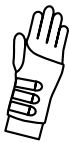

Figure 5: A. CMX Custome-made, B-C. CMX Custome-made saw guides D. Medartis 2.8 TriLock Ulna Shaft Plates



#### Surgical Treatment

Custome-made 3D-printed guides were used to shorten the ulna by 2 mm and de-rotate the head by 15° in the supination direction.



#### Postoperative Treatment

Anti Pro-/Supination splint for 6 weeks until osseous union. Another 6 weeks hand therapy with full Range Of Motion and 1 kg of weight lifting. Full weight bearing after 12 weeks and pain-free osteotomy site and radiological proof of progressive healing.

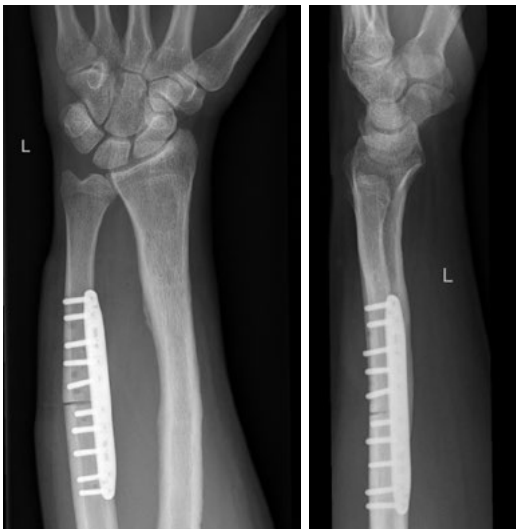

Figure 6: 6 weeks post-op

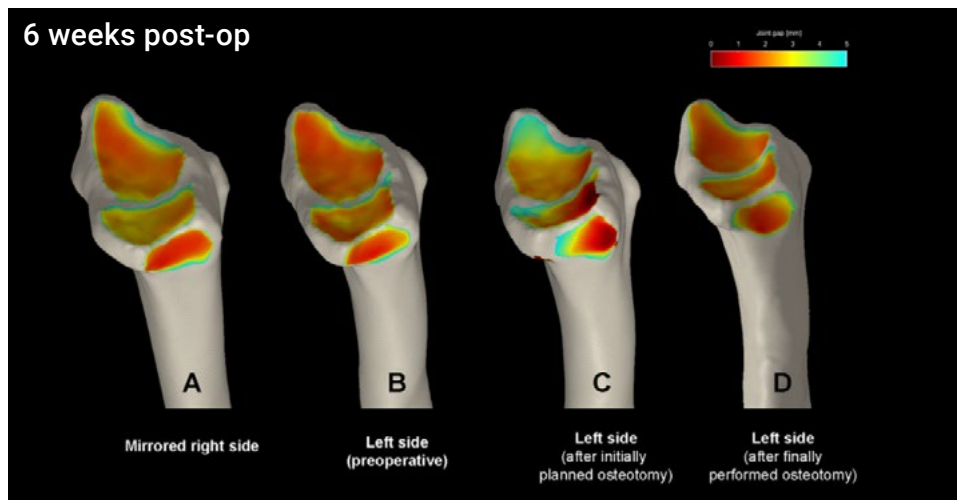


Figure 7. Analysis pre-and postoperatively. A mirrored right side as a reference for virtual surgical planning. B symptomatic left side (pre-operative). C left side after virtually planned situation with an uncentered (dorsally) contact area of the ulna in the sigmoid notch and a dorsal translation of the lunate in the lunate fossa. D final postoperative situation after 6 weeks with a centred position of the ulna and a homogenous distribution of the orange area in the lunate and scaphoid fossa.

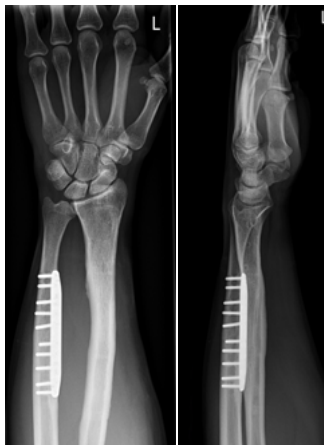

Figure 8-9: Two and a half years after the osteotomy the patient regained full pro- and supination of 90°, extension/ flexion of 70° and radial-/ulnar deviation of 20/0/40°. The wrist clench force was 50 kg on the left and 54 kg on the right side. He is pain-free and climbs again without any limits.



### Conclusion

According to the healthy mirrored contralateral site and simulation of a radius osteotomy, there was no need to perform the osteotomy/lengthening of the radius but a shortening and de-rotation of the ulna. The patient is pain-free with full ROM and had the implant removed 2 1/2 years after surgery.



### References

- 1) Kakar S, Garcia-Elias M. The "Four-Leaf Clover" Treatment Algorithm: A Practical Approach to Manage Disorders of the Distal Radioulnar Joint. *J Hand Surg Am.* 2016;41(4):551-564. doi:10.1016/j.jhsa.2016.01.005

Disclaimer: This case report presents the outcome of an individual patient case and it does not imply any guarantee or warranty in regard to treatment success. A surgeon must always rely on her or his own professional clinical judgment when deciding whether to use a particular product when treating a particular patient. The professional must always comply with the individual product's Instructions For Use ([www.medartis.com/documentation/instructions-for-use](http://www.medartis.com/documentation/instructions-for-use)) as well as all laws and regulations. Medartis is not giving any medical advice. The devices may not be available in all countries due to registration and/or medical practices. All content – such as texts, video and pictures – was created by healthcare professional mentioned in the case report. For further questions, please contact your Medartis representative ([www.medartis.com](http://www.medartis.com)). This information contains products with CE and/or UKCA marking.  
For US only: Federal law restricts this device to sale by or on the order of a physician.

© Medartis 2024. Everything herein is protected by copyright, trademarks and other intellectual property rights, as applicable, owned by or licensed to Medartis or its affiliates unless otherwise indicated. It is forbidden to redistribute, duplicate or disclose, anything herein, in whole or in part, without the prior written consent of Medartis.