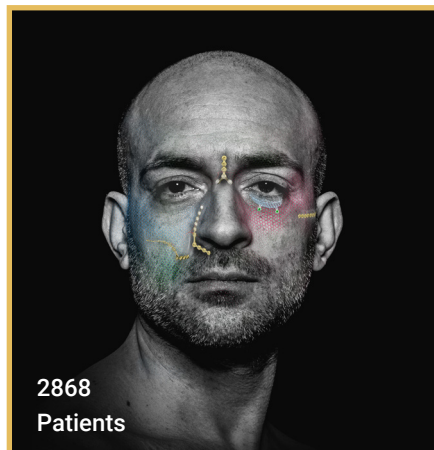
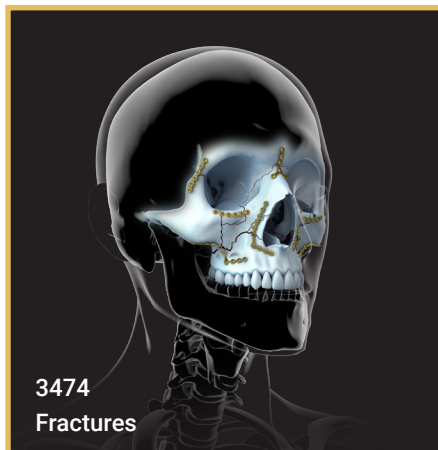


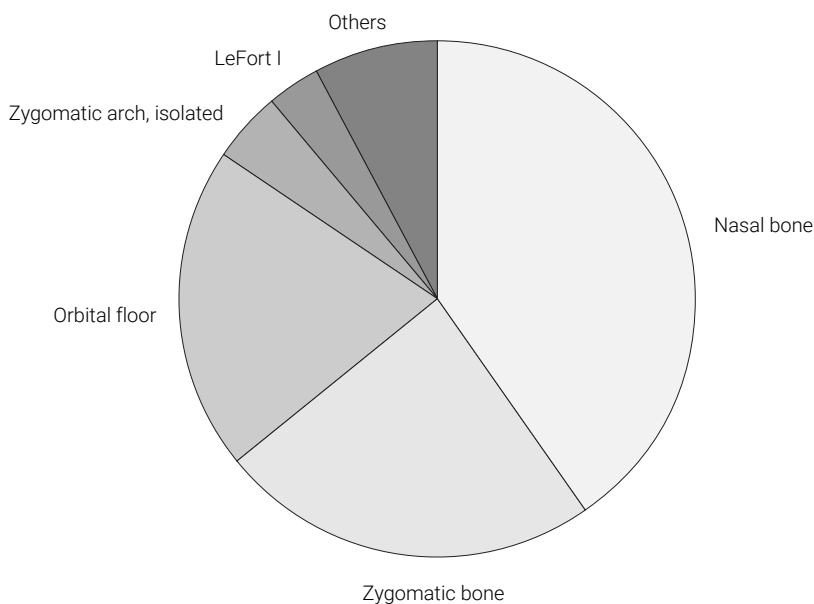
Medartis MODUS Midface plates show excellent results in a long-term retrospective study

Long-term evaluation of treatment protocols for isolated midfacial fractures in a German nation-wide craniomaxillofacial trauma center 2007–2017¹



A long-term study conducted from 2007–2017 in the Department of Cranial- and Maxillofacial Surgery at the Dortmund General Hospital and lead by PD Dr. Dr. Lars Bonitz has evaluated 3474 isolated midface fractures in 2868 patients. This study has shown that in the midface area the vast majority (84.4%) of fractures is composed of three types only: nasal bone fractures, zygomatic bone fractures and orbital floor fractures (40.4%, 23.9% and 20.1% respectively)¹.

This study also aimed at retrospectively assessing the safety and efficacy of the current treatment protocols, including the interdisciplinary collaboration, as well as osteosynthesis procedures. The continuous review of treatment outcomes provides feedback about the treatment quality of a clinic. For this reason, the **Dortmund Cranio-Maxillofacial Trauma Registry** was created.



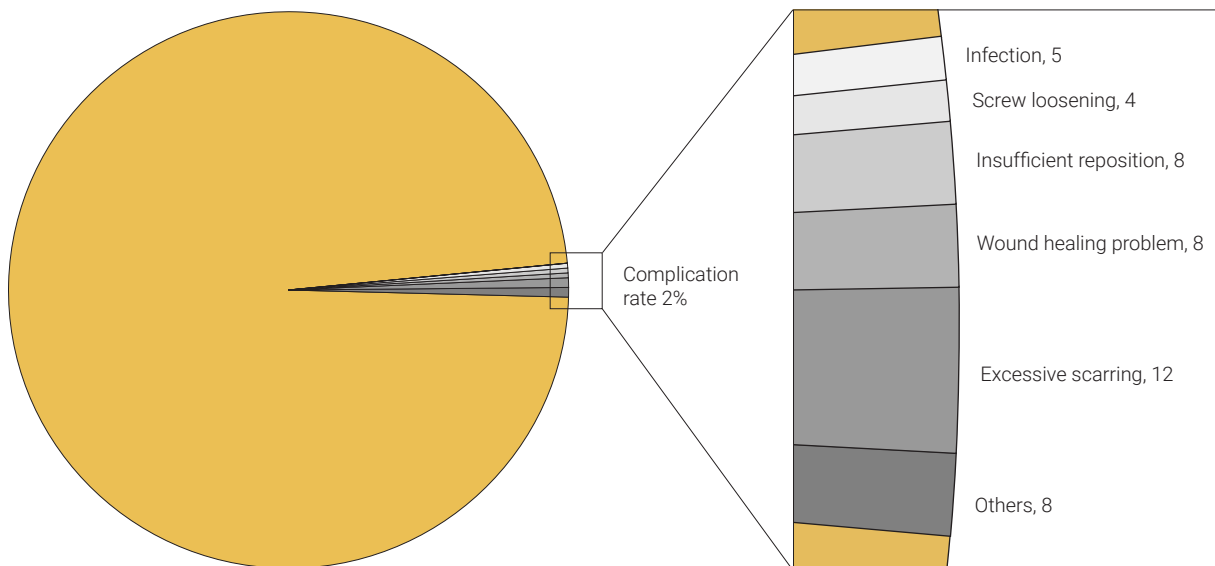
Bone fractures	Total
Nasal bone	1405
Zygomatic bone	832
Orbital floor	700
Zygomatic arch, isolated	152
LeFort I	116
LeFort II	65
Dentoalveolar	61
Maxillary sinus wall	40
Orbital roof	35
Naso-orbito-ethmoid, Type II	20
Naso-orbito-ethmoid, Type I	14
Orbito-ethmoid	12
LeFort III	7
Naso-orbito-ethmoid, Type III	7
Other upper jaw	5
Hard palate	3
Total	3474

Medartis MODUS Midface osteosynthesis implant usage

All fractures in this study were treated with Medartis MODUS plates, 1329 plates were used in total.

The osteosynthesis implants showed excellent stability and contributed to the low complication rate of 2.0% (Clavien-Dindo Class II–IV) compared to other studies that show 4.7%–17%¹. The majority of the complications are procedure- and not hardware-related.

Plate	% of total implants	Total
2.0 mm straight, without bar, 4 holes	37.6%	500
1.5 mm without bar, 4 holes	9.9%	131
1.5 mm without bar, 8 holes	9.0%	120
1.5 mm without bar, 6 holes	8.6%	114
1.5 mm L/Y/T-shaped	8.4%	112
2.0 mm with bar, 4 holes	5.4%	72
2.0 mm without bar, 4 holes	3.9%	52
0.1 mm orbital mesh	3.5%	46



If the osteosynthesis material needs to be removed – either because of complications or by request – the best time to do so is 4–6 months after surgery, thus avoiding osteointegration.

To our knowledge this is the largest retrospective study on the use of midface plates. Medartis is very proud to support this work.

References

1 Bonitz et al., 2021, Nature Scientific Reports, doi.org/10.1038/s41598-021-97858-4

