



medartis®

PRECISION IN FIXATION

SURGICAL TECHNIQUE

Distal Radius System 2.5

APTUS®
Wrist

LITERATURE

1. Krimmer, H., Pessenlehner, C., Haßelbacher, K., Meier, M., Roth, F., and Meier, R. Palmar fixed angle plating systems for instable distal radius fractures [Palmare winkelstabile Plattenosteosynthese der instabilen distalen Radiusfraktur] *Unfallchirurg*, 107[6], 460-467. 2004.
2. Mehling, I., Meier, M., Schloer, U., and Krimmer, H. Multidirectional Palmar Fixed-Angle Plate Fixation for Unstable Distal Radius Fracture [Multidirektionale winkelstabile Versorgung der instabilen distalen Radiusfraktur] *Handchir.Mikrochir.Plast.Chir*, 39[1], 29-33. 2007.
3. Moser, V. L., Pessenlehner, C., Meier, M., and Krimmer, H. Anterior Fixed Angle Plate Fixation of Unstable Distal Radius Fractures [Palmare winkelstabile Plattenosteosynthese der instabilen distalen Radiusfraktur] *Operat.Orthop.Traumatol.*, 16[4], 380-396. 2004.
4. Jakubietz, R. G., Gruenert, J. G., Kloss, D. F., Schindele, S., and Jakubietz, M. G. A Randomised Clinical Study Comparing Palmar and Dorsal Fixed-Angle Plates for the Internal Fixation of AO C-Type Fractures of the Distal Radius in the Elderly *Journal of Hand Surgery, European Volume* 33[5], 600-604. 2008.
5. Figl, M., Weninger, P., Liska, M., Hofbauer, M., and Leixnering, M. Volar fixed-angle plate osteosynthesis of unstable distal radius fractures: 12 months results *Arch.Orthop.Trauma Surg.*, 129[5], 661-669. 2009.
6. Weninger, P., Schueller, M., Drobetz, H., Jamek, M., Redl, H., and Tschegg, E. Influence of an Additional Locking Screw on Fracture Reduction After Volar Fixed-Angle Plating – Introduction of the “Protection Screw” in an Extra-Articular Distal Radius Fracture Model *Journal of Trauma - Injury, Infection, and Critical Care*, 67[4], 746-751. 2009.
7. Figl, M., Weninger, P., Jurkowitsch, J., Hofbauer, M., Schauer, J., and Leixnering, M. Unstable Distal Radius Fractures in the Elderly Patient – Volar Fixed-Angle Plate Osteosynthesis Prevents Secondary Loss of Reduction *Journal of Trauma - Injury, Infection, and Critical Care*, 68[4], 992-998. 2010.
8. Sonderegger, J., Schindele, S., Rau, M., and Gruenert, J. G. Palmar multidirectional fixed-angle plate fixation in distal radius fractures: do intraarticular fractures have a worse outcome than extraarticular fractures? *Arch.Orthop.Trauma Surg.*, 2010.
9. Richter, R., Konnl, E., and Krimmer, H. Strategy of early corrective osteotomy [Strategie der Radiusfrühkorrektur] *Obere Extremität*, 5[2], 92-97. 2010.
10. Haefeli, M., Stober, R., Plaass, C., Jenzer, A., and Steiger, R. First experience with a dorsal plate in modern design for the treatment of distal radius fractures *Journal of Hand Surgery, European Volume* 35E[S1], A-0461. 2010.

Distal Radius System 2.5

CONTENTS

2	Literature
4	Introduction
5	Surgical Principles and Objectives
5	Advantages
5	Indications
5	Contraindications
5	Patient Information
5	Pre-Operative Work-Up
5	Surgical Instruments
5	Anesthesia and Positioning
5	Postoperative Management
6	Removal of Implants
6	Errors, Hazards, Possible Complications
8 – 11	Surgical Technique I – according to Prof. Dr. Hermann Krimmer, Ravensburg, Germany
12 – 17	Surgical Technique II – according to Dr. Christoph Ranft, Kiel, Germany
18 – 19	Correct Application of the TriLock Locking Technology

At a Glance

Distal Radius System 2.5

INTRODUCTION

In recent years, the distal radius fracture, first described by Colles in 1814, has undergone great changes in the approach to its treatment. By using a conservative treatment in a cast or by trying to stabilize the fracture with minimally invasive Kirschner wires, the reduction result of the comminuted fracture is often not or only temporarily maintained. Even the sole external fixation after reduction by ligamentotaxis often does not lead to a permanent maintenance of reduction.

A combination of both methods may prevent a slow impaction, but requires the wires to be left in place for approximately another 6 weeks after the removal of the fixator until bone healing has been accomplished.

The advantage of a volar approach lies in an improved soft tissue coverage, less danger of irritation to the tendons, and better control of reduction of the cortex, in most instances only fractured volarly.

In acute fractures, especially those with multiple fragments and dorsal comminution, screw loosening with secondary loss of correction constituted a major problem. This was caused by the lack of stable bicortical screw purchase, as the screws did not find a proper anchorage in the dorsal comminution. Therefore, an additional cancellous bone graft or the use of a bone substitute inserted dorsally was necessary.

Currently, patients have increased demands and socio-economic factors have become more relevant: an anatomic reconstruction and a permanent reduction have been targeted together with a postoperative immobilization of short duration and early rehabilitation.

Based on the principle of fixed angle devices, new methods of osteosynthesis have been developed. They function like an internal fixator, markedly reduce the mentioned complications, almost always exclude the need for bone grafting and are not limited by a fixed time frame as required by an external fixator.

The volar approach allows an exact reduction and the fixed angle device a permanent maintenance of reduction without the need for additional bone grafts. The postoperative complications, particularly of malunion necessitating a revision, are markedly reduced. The anatomic reduction of distal radius fractures is also indicated in patients of advanced age.

SURGICAL PRINCIPLES AND OBJECTIVES

Reduction and fixation of unstable distal radius fractures with angular stable implants through a radiovolar approach for restoration of shape, length, angle and function

ADVANTAGES

- Good soft tissue coverage
- Stable fixation
- Generally no need for bone grafting in instances of dorsal comminution
- Early functional aftercare possible
- No secondary loss of reduction
- Removal of implants not necessary unless indicated
- High rate of success

INDICATIONS

- Intra- and extra-articular fractures
- Correction osteotomies
- Radiocarpal fusions (arthrodeses)

CONTRAINDICATIONS

- Pre-existing or suspected infections at or near the implantation site
- Known allergies and/or hypersensitivity to foreign bodies
- Inferior or insufficient bone quality to securely anchor the implant
- Patients who are incapacitated and/or uncooperative during the treatment phase
- The treatment of at-risk groups is inadvisable

PATIENT INFORMATION

- Usual general surgical risks such as wound infection, osteitis, vessel, nerve and tendon injury and their sequelae
- Depending on the type of fracture, dorsal, removable forearm plaster slab for 2–4 weeks
- Early motion exercises of the wrist possible
- Implant removal generally not required
- Reflex sympathetic dystrophy
- Limitation of movements due to pain possible; further surgery is sometimes required

PRE-OPERATIVE WORK-UP

- Standard radiographs posterior-anterior, lateral in neutral position
- Possibly computed tomography (CT) in instances of intra-articular fractures
- If a central compression of the radial articular surface is suspected, arthroscopy of the wrist may become necessary to evaluate reduction and diagnose concomitant injuries

SURGICAL INSTRUMENTS

- Set for radius surgery
- Image intensifier

ANESTHESIA AND POSITIONING

- Brachial plexus or endotracheal anesthesia
- Supine
- The arm in supination placed on an arm board, towel roll under the wrist to facilitate reduction
- Esmarch and tourniquet on upper arm
- Single intravenous injection of an antibiotic (such as a second-generation cephalosporin)

POSTOPERATIVE MANAGEMENT

Patients are advised to keep the arm elevated and to move the fingers as soon as feasible (extension of fingers – making a fist, 10 times every hour). Removal of drainage on first or second postoperative day. To permit discharge, the patient must have unlimited motion of the metacarpophalangeal and elbow joints. Otherwise, physiotherapy has to be continued on an inpatient basis.

The wrist is immobilized for 2 weeks with a slab that does not include the thumb. In instances of severe comminution immobilization for 4 weeks is recommended. Suture removal after 2 weeks.

After the first postoperative day hand and fingers are actively moved daily while the slab is slightly released with the goal to be able to make a complete fist and complete extension.

After 2 weeks, the slab is temporarily removed and physiotherapy (active and passive), 5 times weekly, started. The patient is also encouraged to use the hand freely for daily tasks and to do daily exercises on his/her own. Sports activities and heavy work are not to be undertaken until bone consolidation, usually after 6–8 weeks. Until 4 weeks after operation between the active exercises, the slab has to be fixed again.

Comminuted fractures are to be immobilized for 4 weeks. Passive mobilization after temporary removal of the slab begins after 2 weeks depending on the state of the fracture, at the latest after 4 weeks. Other treatment regimens constitute an exception.

REMOVAL OF IMPLANTS

Generally plate removal is not necessary. This is mainly due to the fact that the overall system height can be kept at a minimum utilizing Medartis unique TriLock locking technology. This feature allows for the requirement of a low profile implant system even in the fully angulated state of $\pm 15^\circ$. The very smooth surface in combination with the atraumatic plate edges minimizes soft tissue irritation.

However, metal removal may become necessary when the plate was placed extremely close to the volar rim of the distal radius, i.e. when the flexor apparatus (mainly the tendon of the flexor pollicis longus) gets irritated. If synovitis is suspected, it is advisable to remove the implant. In rare cases of reduced postoperative sensitivity, numbness or when the patient feels uncomfortable with the implant, an explantation is advised.

ERRORS, HAZARDS, POSSIBLE COMPLICATIONS

- Injury to the median nerve or its volar branch: microsurgical repair
- Injury to the radial artery: immediate microsurgical repair
- Hemorrhage: surgical revision, hematoma evacuation, hemostasis and drainage
- A scapholunate ligament injury or a triangular fibrocartilage complex (TFCC) lesion has been missed: carpal collapse with subsequent radiocarpal osteoarthritis, unstable distal radioulnar joint: temporary reduction with Kirschner wires and refixation of the ulnar styloid process
- Intra-articular screw position: change angle of the pre-drilled canal and reinsert screw
- Plate positioning too far distally may cause flexor tendon irritation: reposition plate proximally
- Irritation of the extensor tendons by too long screws: choice of shorter screws or early removal of implants. In instances of tendon rupture: reconstruction of the tendons

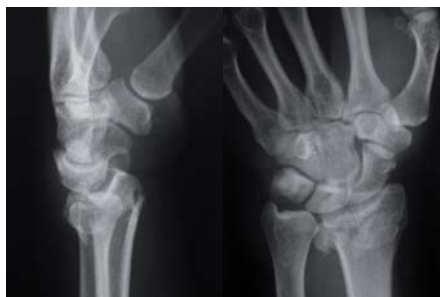- Threat of carpal tunnel syndrome: open carpal canal
- Postoperative swelling and pain: decrease by consequent elevation of the arm, administration of nonsteroidal anti-inflammatory medication, immediate active movement of the fingers to reduce the edema
- Infections are rarely seen; the risk is increased in open fractures or in patients with suppressed immune system. Infections are treated according to established methods
- Reflex sympathetic dystrophy: generally avoidable by controlled and early careful mobilization. If occurring, medical treatment with analgesics, stellate block and physical and occupational therapy, preferably on an inpatient basis. In late stage: surgical arthrolysis
- Even if an optimal reduction has been achieved, a deficit in motion is often present, especially after comminuted intra-articular fractures
- Inadequate reduction of the fragments resulting in malunion: painful limitation of motion and early development of osteoarthritis. Especially after type C fractures revision surgery with denervation of the wrist, partial radioscapholunar arthrodesis or as a salvage operation: hemiresection of the ulnar head according to Bowers or an ulnar shortening according to Kapandji-Sauve

Surgical Technique I

Plate osteosynthesis of an intra-articular extension fracture with dorsal comminuted zone (classification type AO 23-C3) with the multidirectional, angular stable TriLock Distal Radius Fracture Plate

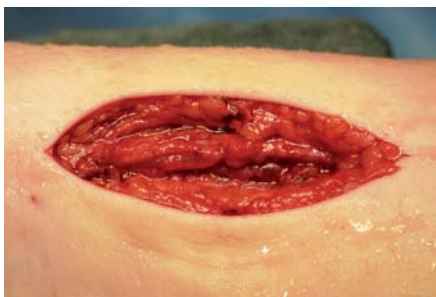Example and technique by Prof. Dr. Hermann Krimmer, Ravensburg, Germany

Clinical Case



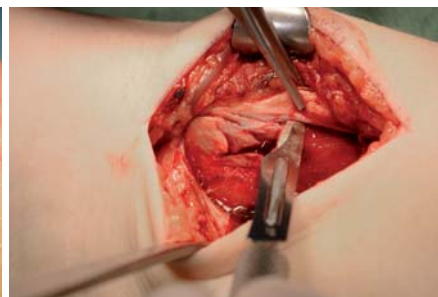
STEP 1

Intra-articular extension fracture with dorsal comminuted zone.



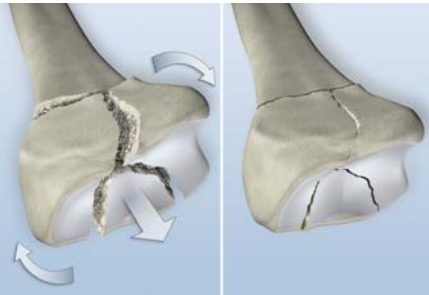
STEP 2

Through an incision approximately 10 cm (4 inch) long that ends 3 cm (1.2 inch) proximal to the wrist, the median nerve, the flexor pollicis longus (FPL) and the flexor carpi radialis (FCR) come into view. If necessary, the incision is continued distally up to the transverse skin fold of the wrist in radial direction in a right or acute angle. If posttraumatic sensory disturbances in the area of the median nerve are present or if the patient suffers from a latent carpal tunnel syndrome, the incision is enlarged towards distal and the carpal canal is opened.



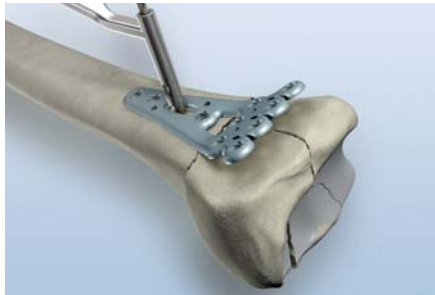
STEP 3

After splitting the fascia, approach through the FCR and the radial vessels. Exposure of the pronator quadratus muscle. Insertion of a Langenbeck retractor and ulnar retraction of the flexor muscles as well as of the median nerve. Sharp detachment of the pronator quadratus muscle with a scalpel leaving a 5 mm (0.2 inch) wide stump attached to the radius. Retraction of the muscle with a periosteal elevator. Opening of the first extensor sheath and subperiosteal detachment of the brachioradialis tendon to facilitate reduction especially in case of fractured radial styloid area. Exposure of the fragments and the fracture gap.



STEP 4

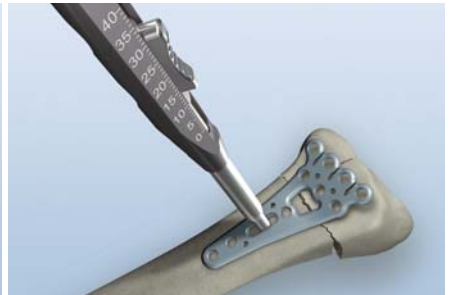
Usually the reduction of the fragments is performed by longitudinal traction in combination with dorsal pressure.



STEP 5

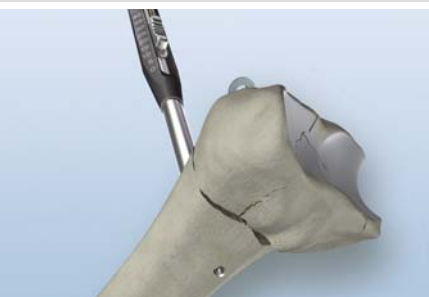Ideally, place the plate centrally to the longitudinal axis distally towards the edge of the so-called watershed line.

Drilling of the longitudinal oriented slot in the shaft using the drill guide and APTUS twist drill for core diameter 2.0 mm (1 purple ring).



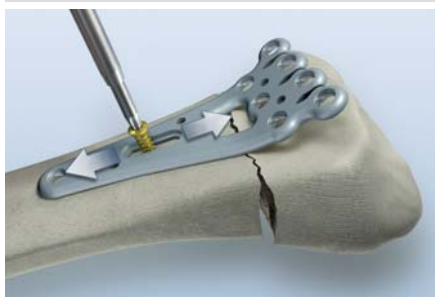STEP 6A

Determine screw length using the depth gauge.



STEP 6B

Reference of the dorsal cortex for bicortical fixation.

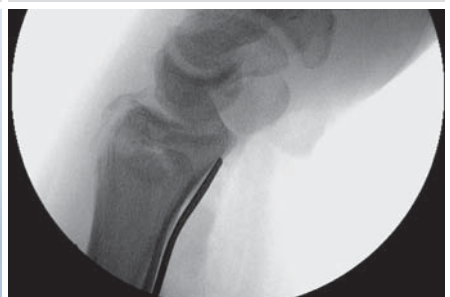

STEP 7

Fixation of the plate with a gold non-locking screw inserted into the longitudinal oriented slot. Image intensifier control to verify the anatomic reduction and the correct plate position. If necessary, the position has to be corrected and the plate to be moved longitudinally and/or laterally.

Note:

If the plate extends beyond the volar rim (watershed line), it could lead to flexor tendon irritation.



STEP 8

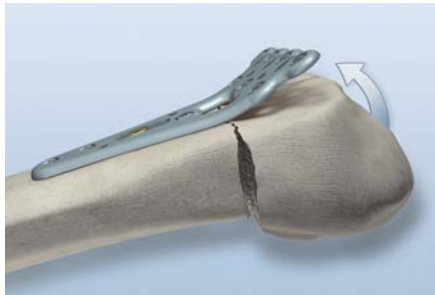Stabilization of the radius fragments: manual check of the distal radioulnar joint.



STEP 9


Note:

It is recommended to place a second shaft screw, ideally a blue TriLock screw*, prior to performing the reduction once the correct plate position has been determined.



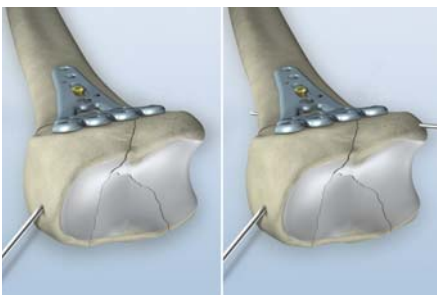
STEP 10A

Reduction by longitudinal traction flexing the injured hand; check with image intensifier control.



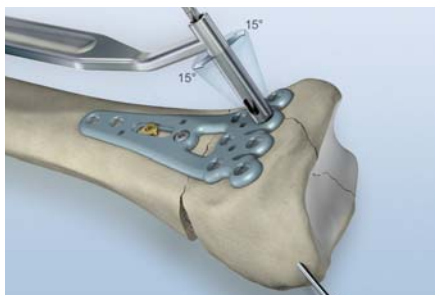
STEP 10B

Final reduction to the plate.



STEP 11

In the case of an unstable fracture, insertion of K-wires can be helpful. This can be done either through holes in the plate in anterior-posterior direction or in an oblique angle through the radial styloid or at the ulnar border.

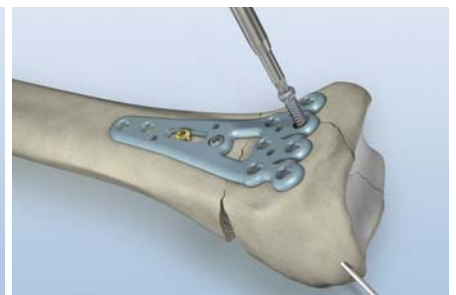


STEP 12

Drilling of the first distal hole using the drill guide and the APTUS twist drill for core diameter 2.0 mm (1 purple ring).

The drill guide can be used multidirectionally in the range of $\pm 15^\circ$ to obtain an angular stable fixation.

Determine the screw length with the depth gauge and insert the first blue TriLock screw in the distal row of holes.



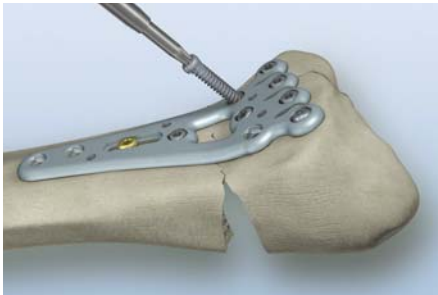
STEP 13

Completion of the insertion of blue TriLock screws in the first distal row of holes.

Note:

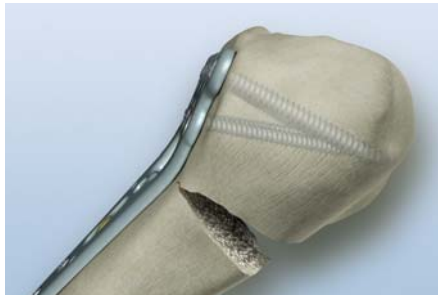
Choose the drill angle parallel to the volar inclination. Image intensifier control to check the subchondral position of the screws.

* For detailed information about the correct use of TriLock locking technology, see pages 18-19.



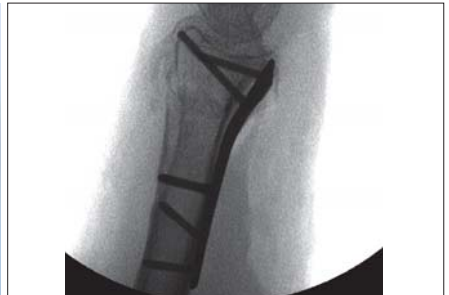STEP 14

Drilling, measuring and insertion of the blue TriLock screws in the second row pointing towards the dorsal rim.



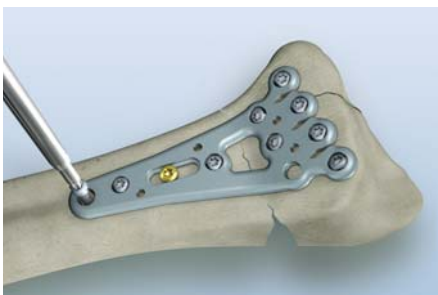STEP 15

The screws of the first row should be angled slightly in a proximal direction while the screws of the second row should be inserted in a distal direction. This subchondral positioning offers an ideal support of the central part of the radius as well as the dorsal rim.



STEP 16

Intra-operative image intensifier control to verify the correct placement of the plate and the screws.



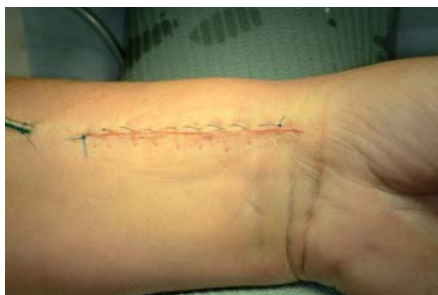STEP 17

Placement of the final screws in the plate shaft.

Note:

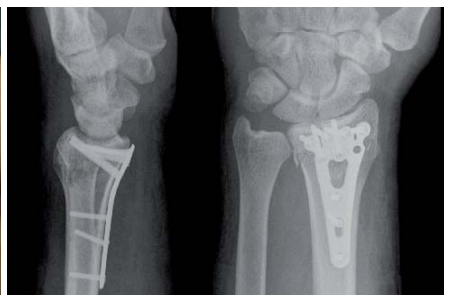It is recommended to use at least 1 blue TriLock screw in the radius shaft to obtain a proper bridging effect.

For ideal results, place at least 3 blue TriLock screws in the most distal row and 2 blue TriLock screws in the second distal row.



STEP 18

Reattachment of pronator quadratus muscle. Insertion of a suction drain. Wound closure to be performed in layers. Application of sterile dressing and posterior forearm slab up to the metacarpal heads in approximately 20° extension of the hand at the wrist.



STEP 19

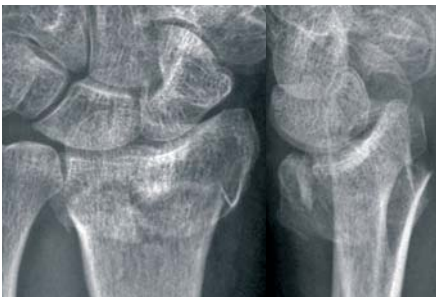Postoperative X-ray control.

Surgical Technique II

Volar osteosynthesis of an unstable radius extension fracture (classification type AO 23-C3) with the short, multidirectional and angular stable TriLock Distal Radius Frame Plate

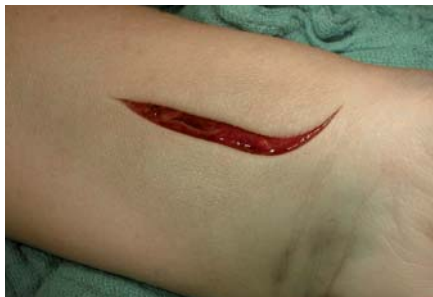Example and technique by Dr. Christoph Ranft, Kiel, Germany

Clinical Case



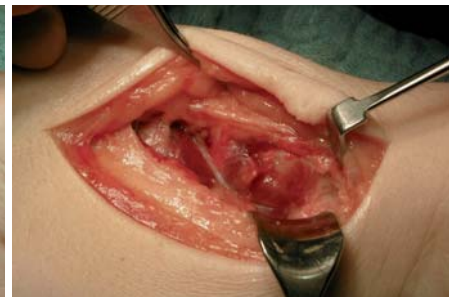STEP 1

Radiograph of a type C3 fracture in a 68-year-old woman.

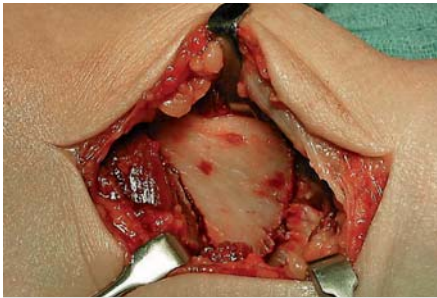


STEP 2A

Small, volar radial approach (6–8 cm (2.3–3.1 inch)), between the radial artery and the tendon of the FCR through the deep fascia to expose the pronator quadratus muscle.

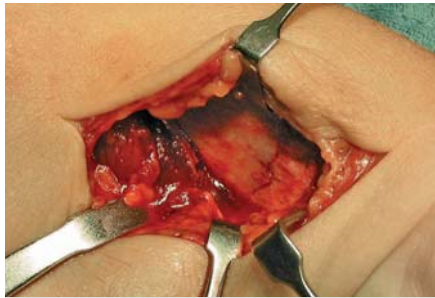

STEP 2B



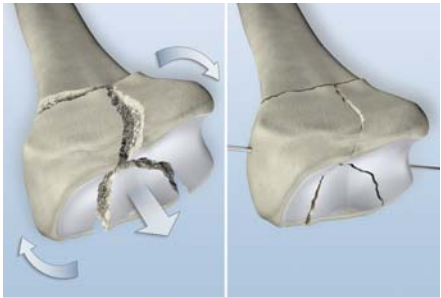
STEP 3

Dissect the pronator quadratus muscle with an L-shaped incision. The fracture becomes visible.



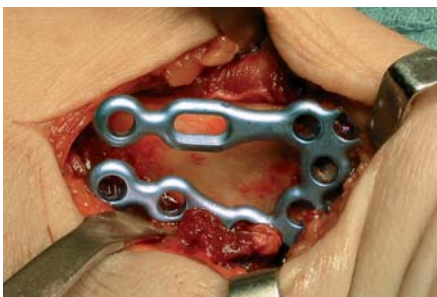STEP 4

First carry out manual volar reduction using the standard combination of distraction and volar flexion over the thumb, which acts as the fulcrum.



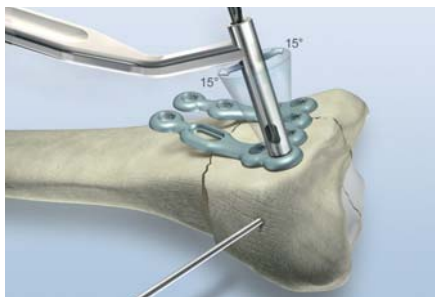
STEP 5

Reduction of the fragments by longitudinal traction in combination with pressure from the dorsal side. Stable fixation of the fragments (monobloc) by use of a K-wire.



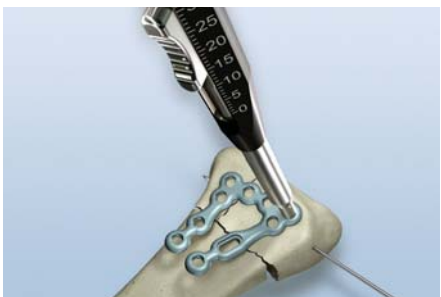STEP 6

Position the plate as distally as possible – using an image intensifier to check the position – so that the screws in the distal row of the plate affix the joint fragment subchondrally.



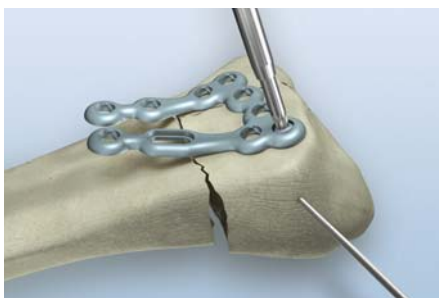
STEP 7

Start fixation with the distal radial hole.



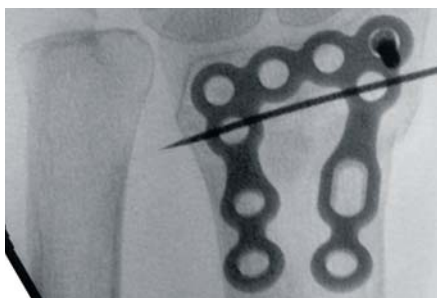
STEP 8

Determining the screw length using the depth gauge.



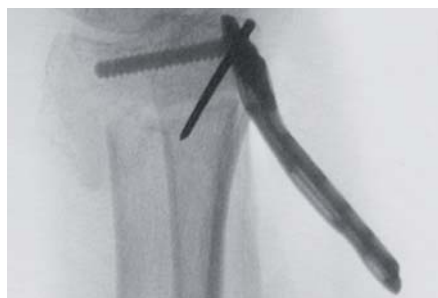STEP 9

Angular stable, subchondral fixation* of the TriLock screw in the distal row of holes.



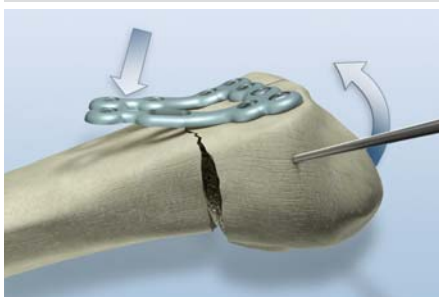
STEP 10A

Intra-operative image intensifier control to verify the correct placement of the plate and the screw.



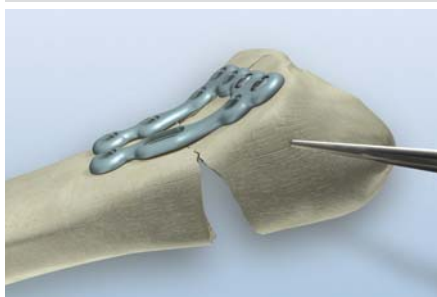
STEP 10B

The angle between the proximal end of the plate and the shaft of the radius is the angle required (complimentary angle) to align the articular surface correctly.

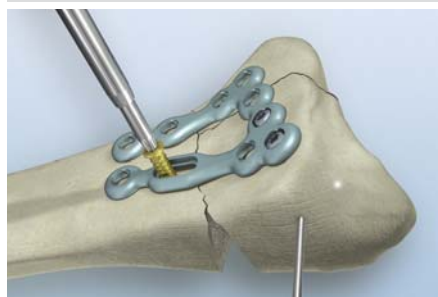


STEP 11

After insertion of ideally 4 angular stable blue TriLock screws, the fracture can be reduced and aligned by leverage on the proximal ends of the plate.



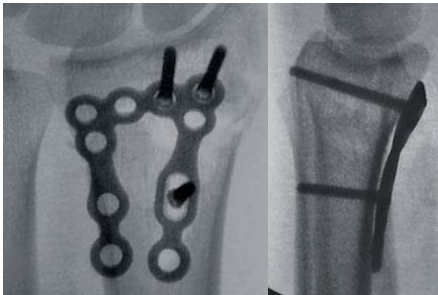STEP 12



STEP 13

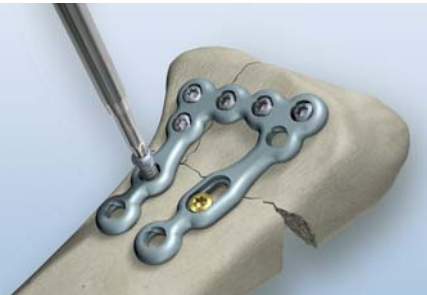Continue fixation using the longitudinal oriented slot with a gold non-locking screw first and check the result with an image intensifier.

* For detailed information about the correct use of TriLock locking technology, see pages 18-19.



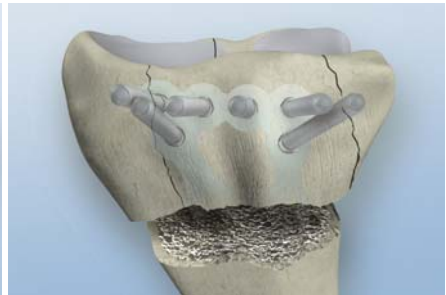
STEP 14

If the image intensifier shows that the correct anatomical position has been achieved, complete the fixation of the fracture by angular stable positioning of the remaining TriLock screws.



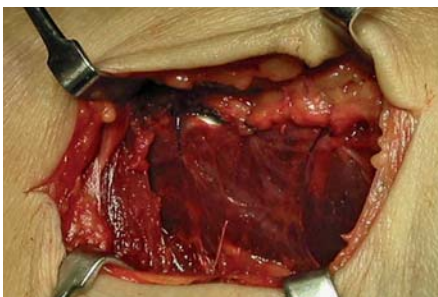
STEP 15

Always perform appropriate checks to ensure that the screws are of the correct length, are locked securely in the plate (they have to click into position), and provide central distal support (first distal screw row) and preferably subchondral dorsal support (second distal screw row) for the dorsal rim.



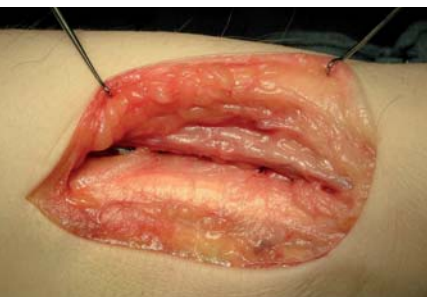STEP 16

The model demonstrates the ideal position of the plate and screws. It shows the very good "carrier" construction which supports the articular surface and the angular stable "bridge" (which acts as a fixator) over the unstable comminuted fracture in the metaphysis.



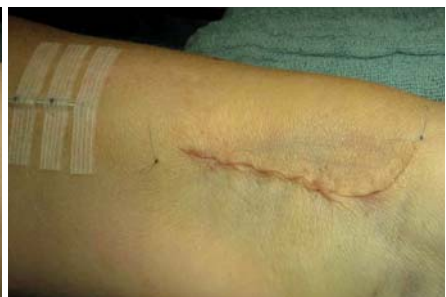STEP 17

Cover the plate by reattaching the pronator quadratus muscle.



STEP 18

Insert a small drain and suture the deep fascia...



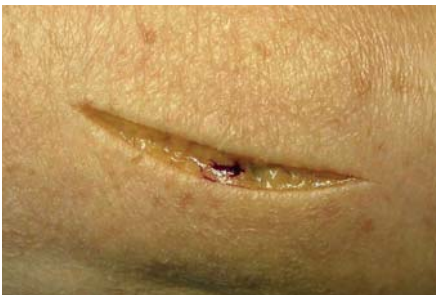
STEP 19

... and suture the skin.

Once the fracture of the radius has been stabilized, the stability of the distal radio ulnar joint (DRUJ) needs to be checked. If it is unstable, the ulnar styloid process – which is usually fractured – and therefore the ligament for the ulna head, must be refixed in an appropriate way.

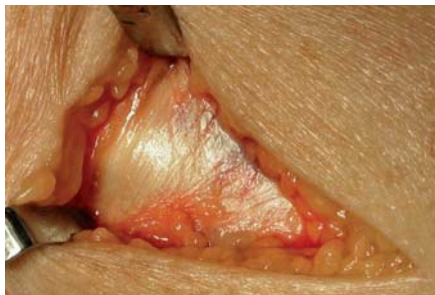If concomitant scapholunate instability is suspected, cinematography of the wrist under image intensifier control must be carried out. If ligament instability is confirmed, reposition the scaphoid and lunate bones and carry out a typical transfixation of the carpal bones with 1.6 mm Kirschner wires.

The dorsal comminuted fracture of the metaphysis is usually extensive; if a rupture of the extensor pollicis longus (EPL) tendon due to wear is to be expected, a slight addition to the procedure can reliably help to prevent this problem from occurring:



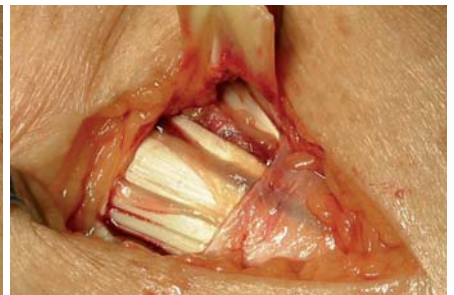STEP 20

Dorsal access 3.5 cm (1.4 inch) long in a distal and central position over the radius.



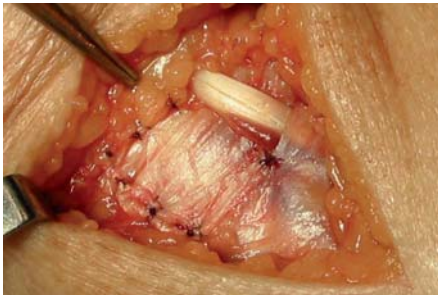
STEP 21

Expose the extensor retinaculum at the Lister's tubercle 2 cm (0.8 inch) in an ulnar direction from it.



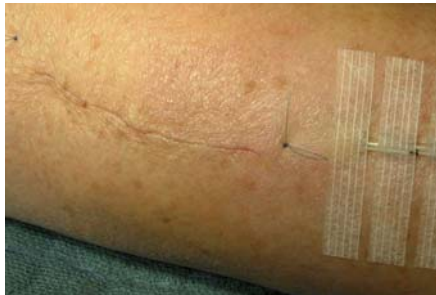STEP 22

Make a U-shaped incision in the extensor retinaculum at the ulnar side of the tuberculum to form a flap about 2 cm (0.8 inch) wide and 1.5 cm (0.6 inch) long. Open the third compartment.



STEP 23

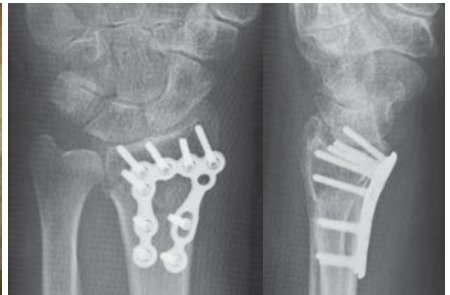
Lift the EPL tendon out of its compartment – superficial erosion of the tendon due to sharp fragments of the dorsal cortex in the comminuted area in the metaphysis is often seen. Draw the flap of the retinaculum under the EPL tendon and fix ulnarly. This protects the tendon from further irritation.



STEP 24

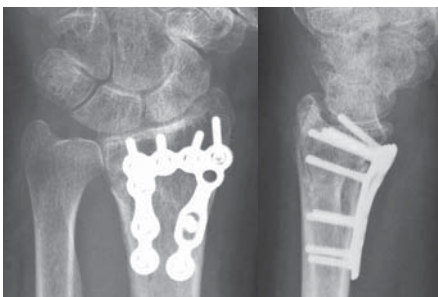
Insert a small drain, suture the skin, release tourniquet.

Once reperfusion has been established, apply a dry dressing. Immobilize the wrist with a dorsal cast which must not be applied too tightly in a functional position.



STEP 25

A postoperative X-ray in the cast shows an anatomical reconstruction and a very good position of the implant.



STEP 26

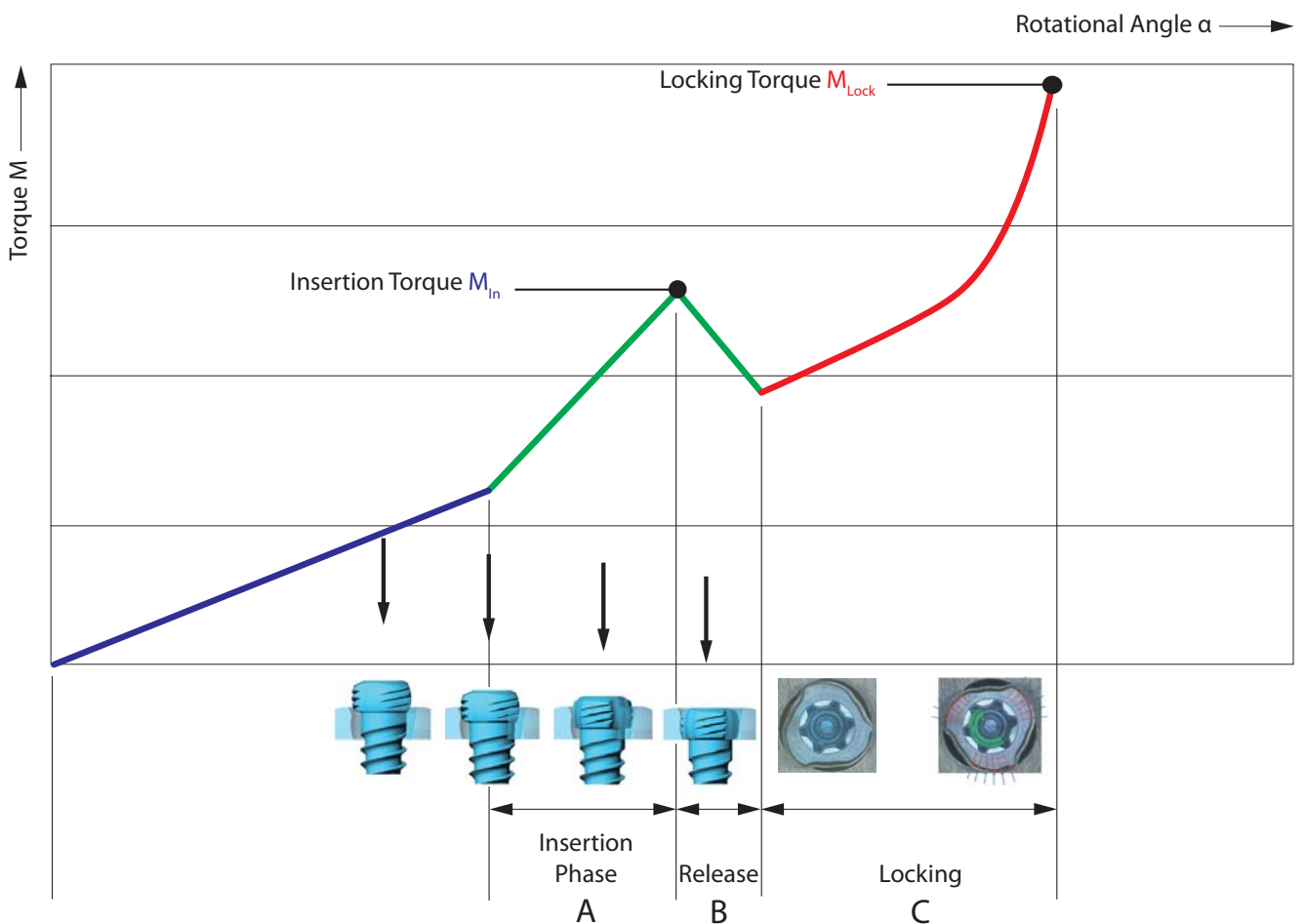
4 weeks postoperatively, the anatomical reconstruction is unchanged and bone healing of the fracture has taken place.

CORRECT APPLICATION OF THE TRILOCK LOCKING TECHNOLOGY

The screw is inserted through the plate hole into a pre-drilled canal in the bone. An increase of the tightening torque will be felt as soon as the screw head gets in contact with the plate surface.

This indicates the start of the “Insertion Phase” as the screw head starts entering the locking zone of the plate (section “A” in the diagram). Afterwards, a drop of the tightening torque occurs (section “B” in the diagram). Finally the actual locking is initiated (section “C” in the diagram) as a friction connection is established between screw and plate when tightening firmly.

The torque applied during fastening of the screw is decisive for the quality of the locking as described in section “C” of the diagram.



**CORRECT LOCKING ($\pm 15^\circ$) OF THE TRILOCK SCREWS
IN THE PLATE**

Visual inspection of the screw head projection provides an indicator of correct locking. Correct locking has occurred only when the screw head has locked flush with the plate surface (figures 1+3). However, if the screw head can still be seen or felt (figures 2+4), the screw head has not completely entered the plate and reached the locking position. In this case the screw has to be retightened to obtain full penetration and proper locking.

Do not overtighten the screw, otherwise the locking function cannot be guaranteed anymore.

Correct: LOCKED

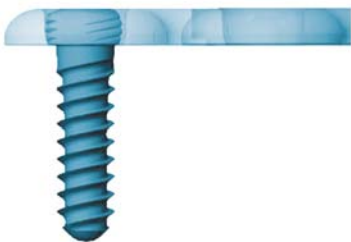

Figure 1

Incorrect: UNLOCKED




Figure 2

Correct: LOCKED





Figure 3

Incorrect: UNLOCKED

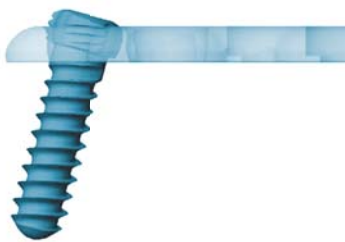

Figure 4



WRIST-01020001_v2 / © 02.2011, Medartis AG, Switzerland. All technical data subject to alteration.

HEADQUARTERS

Medartis AG | Hochbergerstrasse 60E | 4057 Basel/Switzerland
P +41 61 633 34 34 | F +41 61 633 34 00 | www.medartis.com

SUBSIDIARIES

Australia | Austria | France | Germany | Mexico | New Zealand | Poland | UK | USA

For detailed information regarding our subsidiaries and distributors, please visit www.medartis.com.